

NeuroQ™



Quantitative Analysis for Neuroimaging Technology

**Display and Analysis Program
Version 3.7**

Operator Guide

Copyrights, Trademarks, Restrictions

© Copyright 2005-2015, by Syntermed, Inc.

All rights reserved.

Revision 12, Published 2015

Printed in the United States of America

Syntermed reserves the right to modify the design and specifications contained herein without prior notice. Please contact your local Sales Representative for the most current information.

No part of this documentation may be reproduced or transmitted in any form by any means, electronic or mechanical, without written permission of Syntermed.

NeuroQ™ is a registered trademark of Syntermed, Inc.

Insight Segmentation and Registration Toolkit (ITK), Copyright (c) 1999-2008 Insight Software Consortium, All rights reserved.

Table of Contents

OVERVIEW	4
PROCESSING	5
NEUROQ™ QUALITY CONTROL SCREEN	6
NEUROQ™ ANALYSIS SCREEN (LEFT SIDE)	11
NEUROQ™ DISPLAY SCREEN (RIGHT SIDE)	16
NEUROQ™ COMPARE DISPLAY SCREEN.....	18
NEUROQ™ PET/CT DISPLAY SCREEN.....	19
EQUAL™ ANALYSIS	20
CONTROL DATABASE.....	23
AMYLOID OVERVIEW, PROCESSING, AND DISPLAY	25
SPECT OVERVIEW, PROCESSING AND DISPLAY	27
DESCRIPTION OF EXAMPLE PATIENT'S.....	29
DEMO, CASE1 – NORMAL CASE	29
DEMO, CASE2 – MILDLY ABNORMAL	30
DEMO, CASE3 – SEVERELY ABNORMAL.....	32
REFERENCES FOR CASE STUDY 2.....	34
REFERENCES FOR CASE STUDY 3.....	34
REFERENCES RELATED TO NEUROQ™ DEVELOPMENT.....	35
APPENDIX I - BRAIN PET SCAN VISUAL INTERPRETATION	37
APPENDIX II - REGIONAL HYPOMETABOLISM IDENTIFIED BY FDG-PET.....	39
APPENDIX III – MEDICARE CHECKLIST TO DETERMINE FDG-PET DEMENTIA	40
APPENDIX IV - USING CLINICAL BRAIN PET FOR EVALUATION OF DEMENTIA	42

NeuroQ™

Quantitative Analysis for Neuroimaging Technology Version 3.7

OVERVIEW

The **NeuroQ™** Display and Analysis Program has been developed to aid in the assessment of human brain scans through quantification of mean pixel values lying within standardized regions of interest, and to provide quantified comparisons with brain scans derived from FDG-PET or HMPAO SPECT studies of defined groups having no identified neuropsychiatric disease or symptoms, i.e., asymptomatic controls (AC). The Program provides automated analysis of brain PET and SPECT scans, with output that includes quantification of relative activity in 240 different brain regions, as well as measures of the magnitude and statistical significance with which activity in each region differs from mean activity values of brain regions in the AC database. In addition, the program includes NeuroQ™ Quality Control Screen, PET/CT display screen, patient study comparison analysis, amyloid analysis and EQuAL™ a tool for evaluating temporal lobe Epilepsy, PET/MR display screen, saving the cluster screen, remembering display settings, auto processing, and ability for the user to generate their own normal limit and use within the NeuroQ™ application. The new features of version 3.7 include a quantitative analysis of HMAPO SPECT. This manual describes the display and analysis features of the program, and their end-user operation.

Program Description

The NeuroQ™ Program is indicated to:

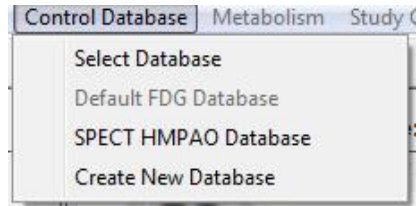
- 1) Assist with regional assessment of human brain scans, through automated quantification of mean pixel values lying within standardized regions of interest (S-ROI's).
- 2) Assist with comparisons of the activity in brain regions of individual scans relative to normal activity values found for brain regions in FDG-PET scans, through quantitative and statistical comparisons of S-ROI's.
- 3) Compare activity in brain regions of individual scans between two studies from the same patient.
- 4) Compare activity between symmetric regions of interest within the brain PET study.
- 5) Perform an image fusion of the patients PET and CT data.
- 6) Provide analysis of amyloid uptake levels in the brain.

The program requires the operator to select the patient's FDG or HMPAO SPECT Brain scan. Following a number of internal checks on the data (e.g., accurate radiopharmaceutical), for FDG, the operator has to initiate the quality control sequence which includes setting the reference line over the brain, perform a scalp correction on the data, subject the data to rigid registration to correct for brain tilt, and perform elastic spatial reformatting or normalization of the patient's scan into a standardized volumetric space. Following this step, the program determines the uptake in 240 ROIs, normalized to the uptake in the subject's sensorimotor cortical region (S-ROI). The uptake in the ROIs is then compared to a normal data base of uptakes, based upon uptake in the corresponding S-ROIs determined in 50 normal subjects without identified neuropsychiatric disease. Any region with an uptake below 1.65 S.D of the mean, established from the normal data base is considered abnormal.

Processing

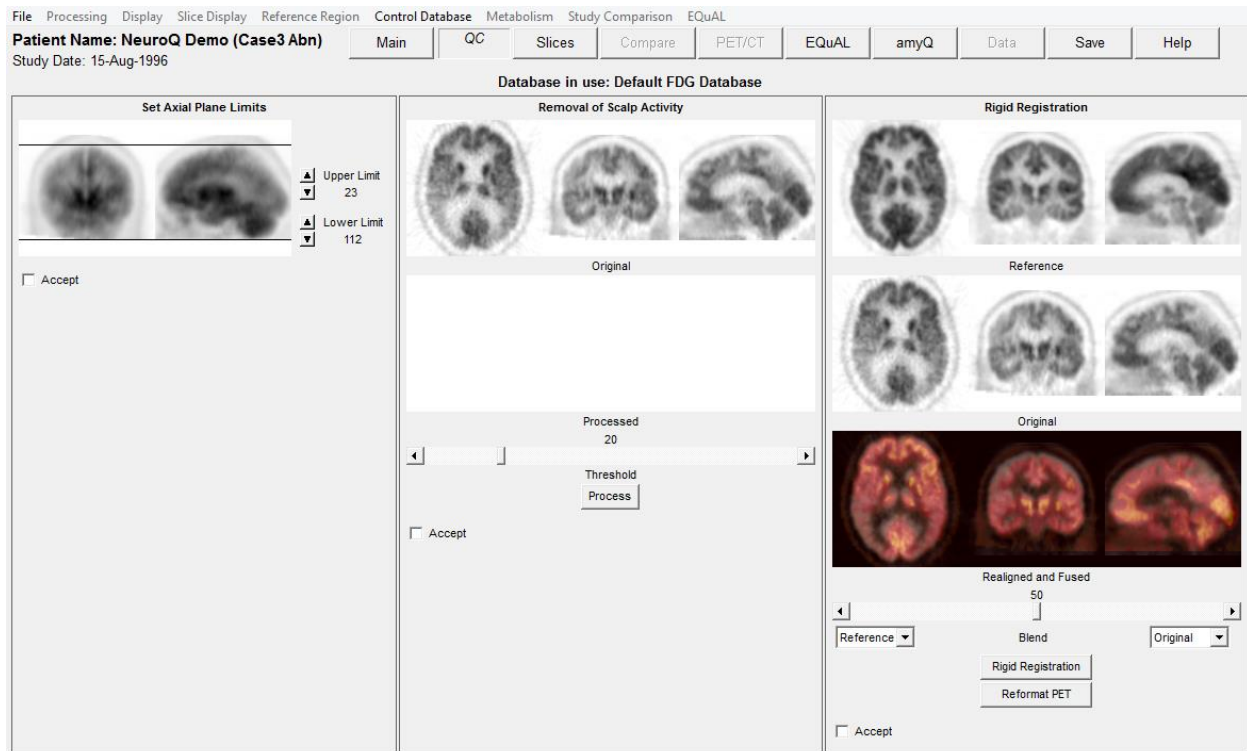
The FDG PET or HMPAO SPECT files in DICOM format need to be selected and imported into the NeuroQ™ program. Once this is done the initial NeuroQ™ Quality Control Screen will be displayed.

- 1) Note: when the study is first launched the Database in use should list the appropriate database for the patient selected. If the database is incorrect then go to the Control Database menu item and select the proper normal limit database before proceeding to the processing section.



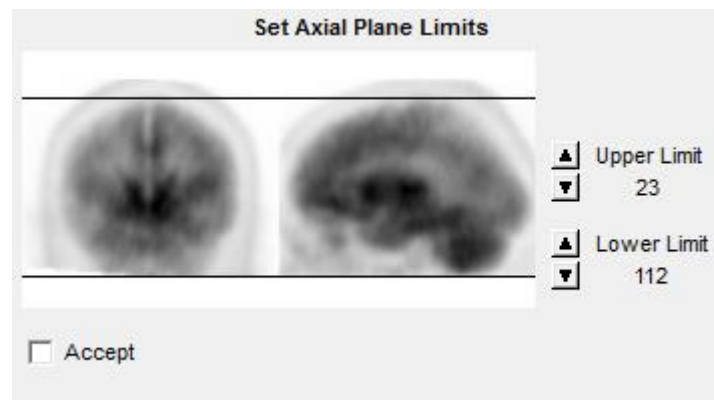
- 2) Optimal processing requires that you perform the following steps for FDG-PET: set axial limits, perform scalp correction, and perform rigid registration. These processing steps are described below. Note: the QC is not performed for HMPAO SPECT studies.

NeuroQ™ Quality Control Screen



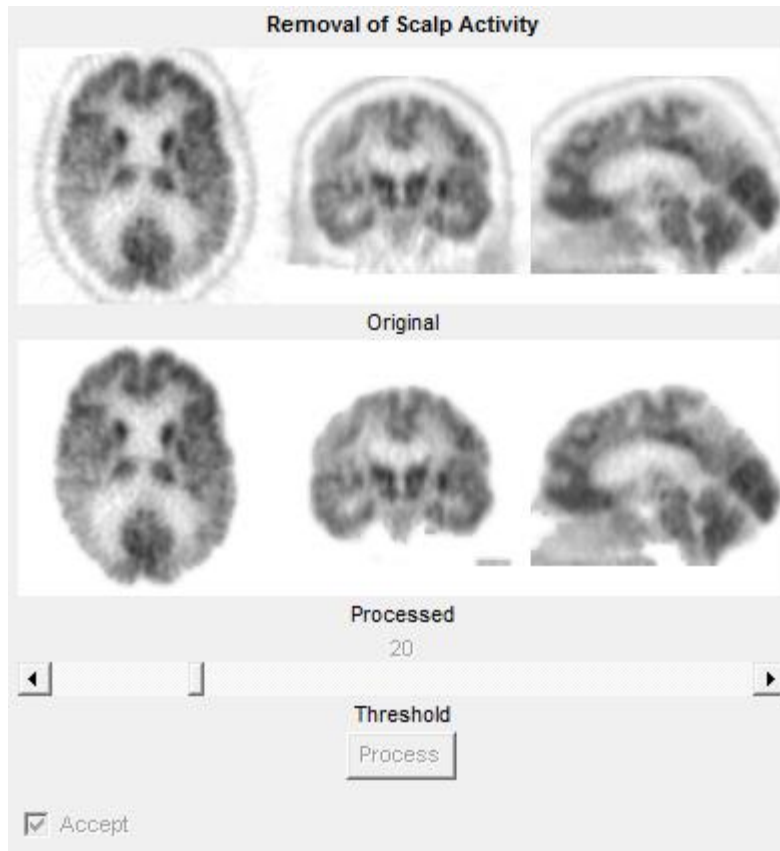
The Quality Control Screen is comprised of three sections: Set Axial Plane Limits, Removal of Scalp Activity, and Rigid Registration.

Set Axial Plane Limits



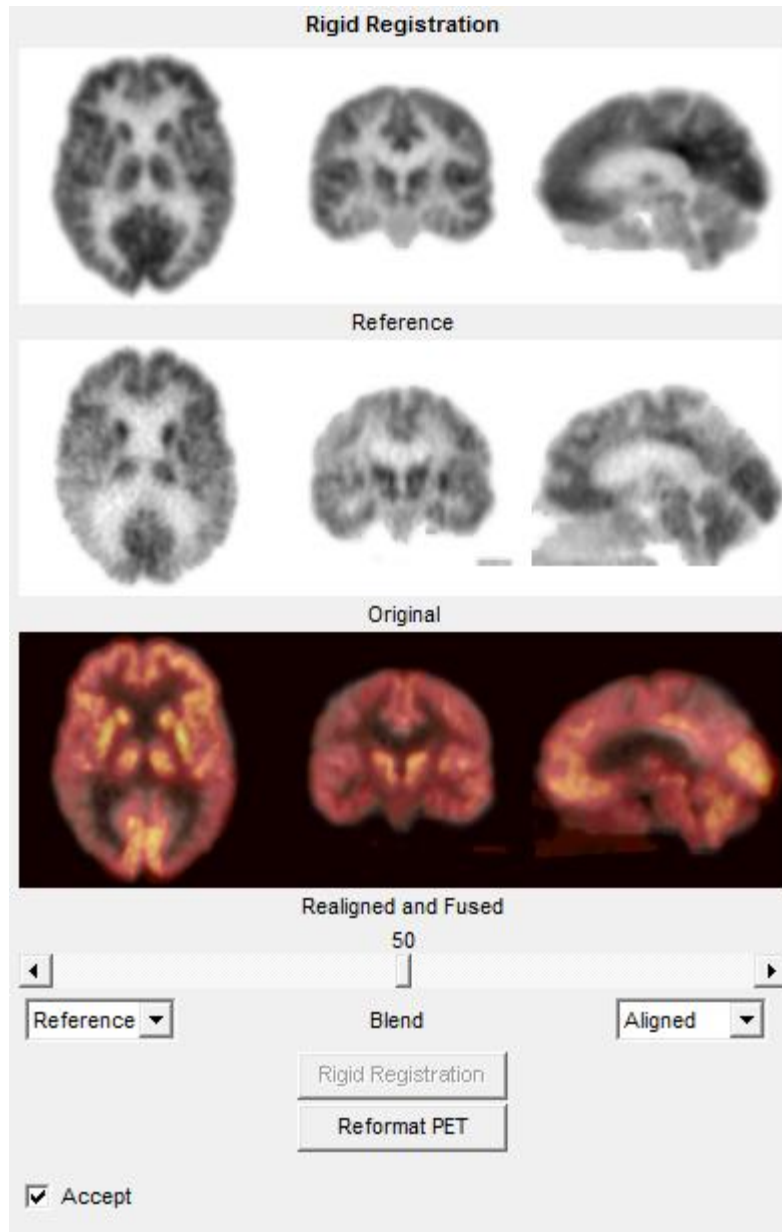
This feature allows the user to set the upper and lower limits for reconstruction by clicking the up and down arrows to move the lines. The limits can also be set by moving the cursor to a point on the image and click left to set the limit. The limits should be set so that only the brain images are included in the reconstruction. When the limits are set to the proper location check the Accept box.

Removal of Scalp Activity



This feature allows for the removal of the scalp activity around the brain. In some cases there is excessive scalp activity which can interfere with the reformatting of the patients study to match the normal template. Move the slider bar to the desired threshold and then click on the Process button. It is recommended that the scalp correction be applied to every study and use 20 as the setting. The processed images are shown in the bottom row. Triangulation is enabled on these images by clicking left on any image and it will show you the plane for that location on the other two images. When the images are processed for scalp correction the Accept box will be checked.

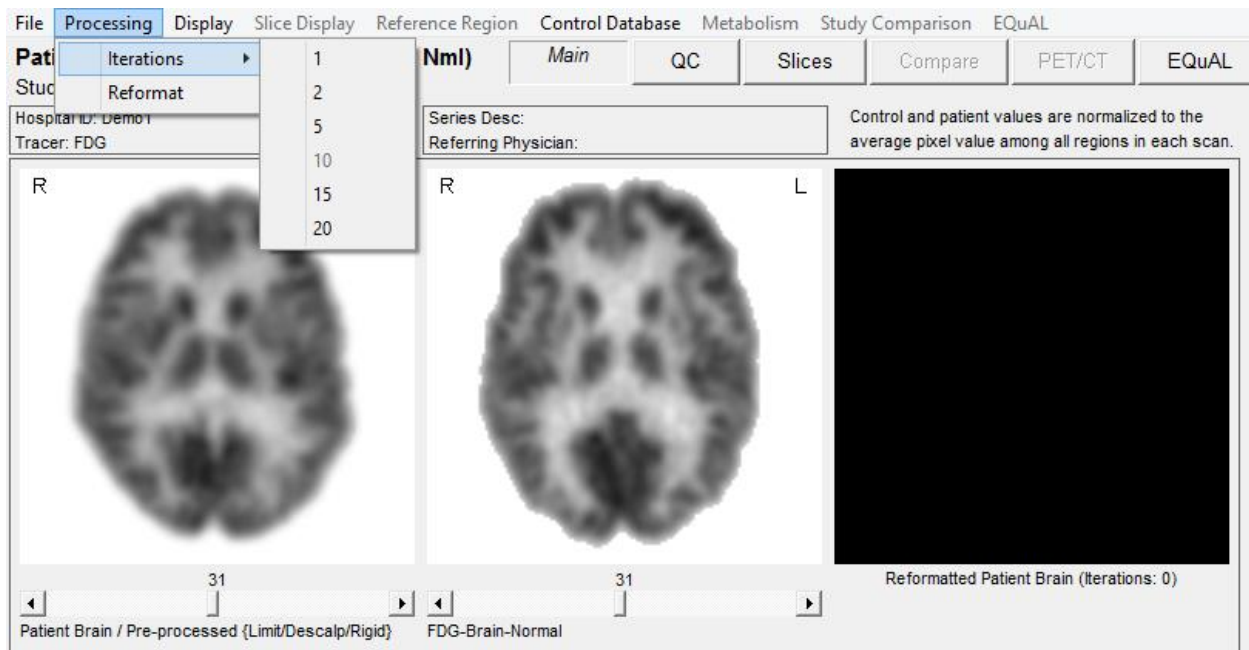
Rigid Registration



The Rigid Registration allows for applying additional registration prior to the reformatting process used in NeuroQ™. This additional registration is helpful in cases where the patient's head has excessive tilt. It is recommended that rigid registration be applied to all studies prior to reformatting. The top row shows the normal template as the reference image, the middle row are the patient's images, and the bottom row are the fused reference and patient images after realignment. Triangulation is enabled on these images by clicking left on any image, and it will show you the plane for that location on the other two images. When the images are processed, the Accept check box will be checked. If all of these QC steps are performed, then the recommended iterations for reformatting is 10. If the Reformat button is selected, then the study will automatically be reformatted with 10 iterations.

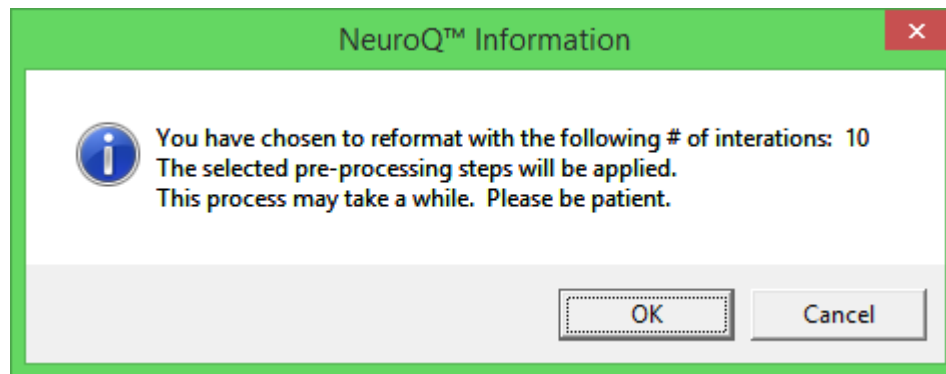
Processing (cont'd)

- 3) The next step involves reformatting the patient's transaxial slices to fit the normal template transaxial slices. This is performed by selecting the Reformat PET (or SPECT) button. The registration algorithm used for reformatting of the patient's data is a robust spatial transformation method published by Henry Huang and Ed Hoffman, along with their collaborators. It was originally described in IEEE (Tai et al., *IEEE Trans. Nucl. Sci. NS-44* 1997; **4**: 1606-1612.)

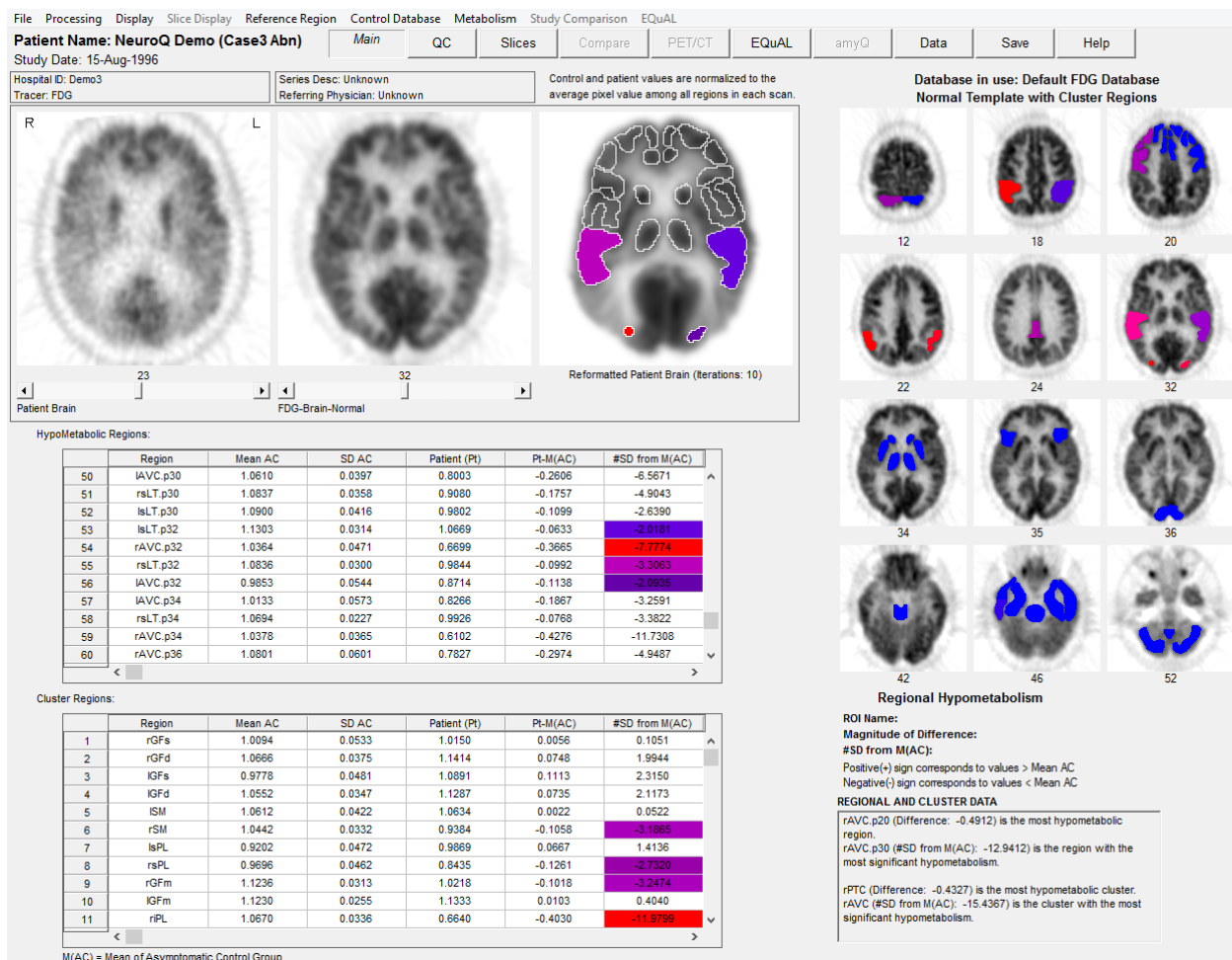


Note: in some cases the user may want to use a different number of iterations. This is performed from the Processing menu item and select Reformat from the drop down box as shown above.

- 4) For the most standard use of the Program (i.e., comparing an individual scan from the end-user's site to NeuroQ™'s built-in database), if all of the QC processing is performed as described in the previous section then it is recommended to use 10 iterations, and this is the only option that normally will ever need to be selected. The other choices in the Iterations pull-down menu (1, 2, 5, 15 and 20) have been retained in order to allow flexibility to use the tool in other ways: for example, 1) rapid testing of software operability by selecting a small number of iterations, 2) processing a batch of scans acquired at the end-user's site to create a new database with whatever number of iterations is desired, 3) sequential use of the reiteration routine, such as adding another 5 iterations to a scan that had already been re-iterated 20 times in order to obtain a closer spatial fit in a case where the individual's original scan is structurally very different from the normal template scan, 4) various research applications, etc.
- 5) Once the Reformat button has been selected, an information box will be displayed informing you of the number of iterations you have selected.



- 6) Click on the OK button and the patient's study will be reformatted to align with the normal template. On a current processor (core i7) the reformatting will take approximately 1 minute.
- 7) Once the study is reformatted the final quantitative analysis output will be displayed which is shown below.



The left side of the window contains the “NeuroQ™ Analysis” screen and the right side contains the “NeuroQ™ Display” screen. These displays are defined below.

NeuroQ™ Analysis Screen (Left Side)

1. File Menu
2. Processing Menu
3. Display Menu
4. Reference Region Menu
5. Control Database Menu
6. Metabolism Menu
7. Study Comparison Menu
8. EQuAL Menu
9. PET/CT Menu
10. amyQ Menu
11. Data Menu
12. Save Menu
13. Patient Name: NeuroQ Demo (Case3 Abn)
14. Hospital ID: Demo3
15. Tracer: FDG
16. Series Desc: Unknown
17. Referring Physician: Unknown
18. Control and patient values are normalized to the average pixel value among all regions in each scan.
19. Database in use: Default FDG Database
20. Normal Template with Cluster Regions

14. Patient Brain
15. FDG-Brain-Normal
16. Reformatted Patient Brain (Iterations: 10)

19. HypoMetabolic Regions:

Region	Mean AC	SD AC	Patient (Pt)	PL-M(AC)	#SD from M(AC)
50	IAVC.p30	1.0610	0.0397	0.8003	-0.2806
51	rsLT.p30	1.0837	0.0358	0.9080	-0.1757
52	IsLT.p30	1.0900	0.0416	0.9802	-0.1099
53	IsLT.p32	1.1303	0.0314	1.0669	-0.0633
54	rAVC.p32	1.0364	0.0471	0.6699	-0.3665
55	rsLT.p32	1.0836	0.0300	0.9844	-0.0992
56	IAVC.p32	0.9853	0.0544	0.8714	-0.1138
57	IAVC.p34	1.0133	0.0573	0.8266	-0.1867
58	rsLT.p34	1.0694	0.0227	0.9926	-0.0768
59	rAVC.p34	1.0378	0.0365	0.6102	-0.4276
60	rAVC.p36	1.0801	0.0601	0.7827	-0.2974

20. Cluster Regions:

Region	Mean AC	SD AC	Patient (Pt)	PL-M(AC)	#SD from M(AC)
1	rGFs	1.0094	0.0533	1.0150	0.0056
2	rGFd	1.0666	0.0375	1.1414	0.0748
3	IGFs	0.9778	0.0481	1.0891	0.1113
4	IGFd	1.0552	0.0347	1.1287	0.0735
5	ISM	1.0612	0.0422	1.0634	0.0022
6	rSIM	1.0442	0.0332	0.9384	-0.1058
7	IsPL	0.9202	0.0472	0.9869	0.0667
8	rsPL	0.9696	0.0462	0.8435	-0.1261
9	rGFm	1.1236	0.0313	1.0218	-0.1018
10	IGFm	1.1230	0.0255	1.1333	0.0103
11	rPL	1.0670	0.0336	0.6640	-0.4030

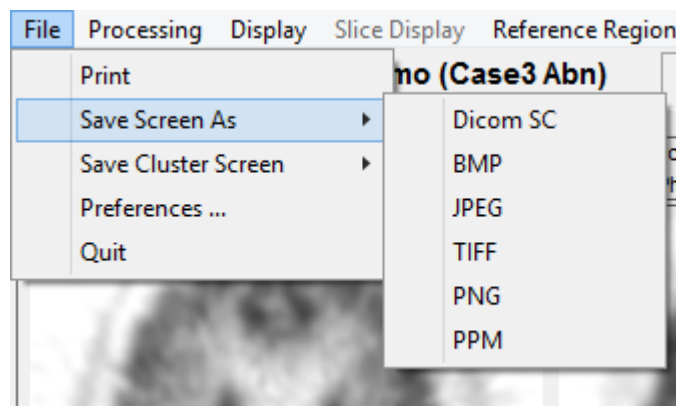
Regional Hypometabolism

ROI Name:
Magnitude of Difference:
#SD from M(AC):
Positive(+) sign corresponds to values > Mean AC.
Negative(-) sign corresponds to values < Mean AC

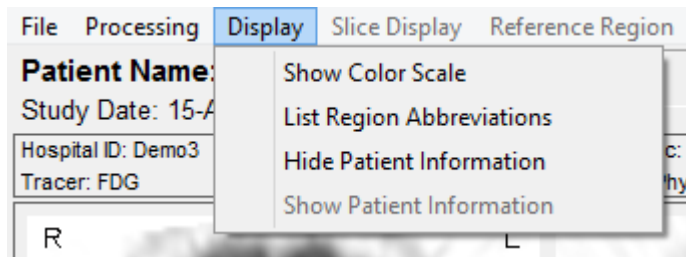
REGIONAL AND CLUSTER DATA

rAVC.p20 (Difference: -0.4912) is the most hypometabolic region.
rAVC.p30 (#SD from M(AC): -12.9412) is the region with the most significant hypometabolism.
rPTC (Difference: -0.4327) is the most hypometabolic cluster.
rAVC (#SD from M(AC): -15.4367) is the cluster with the most significant hypometabolism.

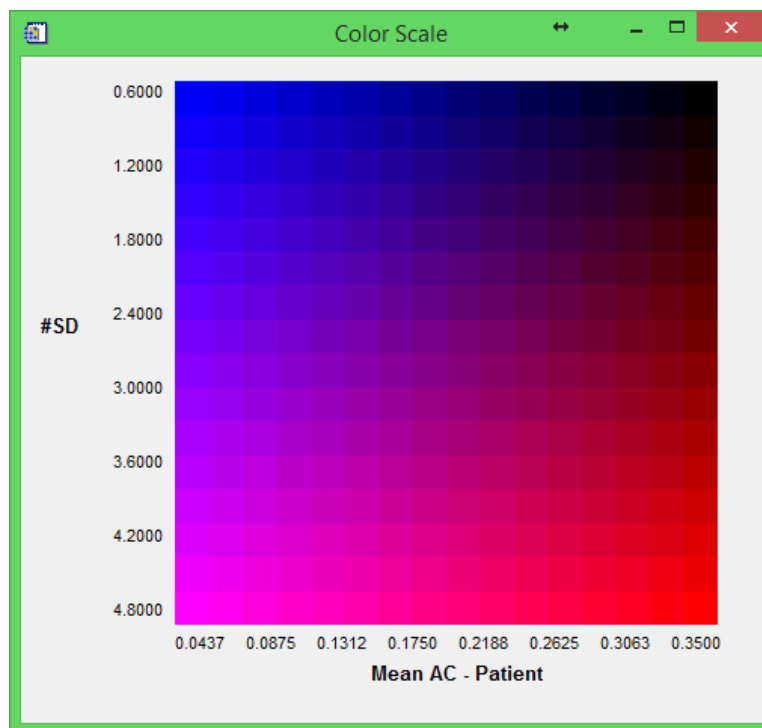
1. File Menu – this allows the user to print the current screen, save the screen in various formats, save just the cluster screen, set preferences options for language and the default database, and allows the user to quit from the application. The options for save screen formats are listed below. Note: The DICOM Screen Capture allows the data to be saved in a format acceptable by PACS systems.



2. Processing Menu – allows user to reformat the brain, the default number of iterations is 10 and that value will be used if the Reformat option is selected from the Processing drop down list. This processing step is described above in the Processing section.
3. Display Menu – the display menu allows you to display the Color Scale, display a list of region abbreviations, and hide patient information. The options are shown below.

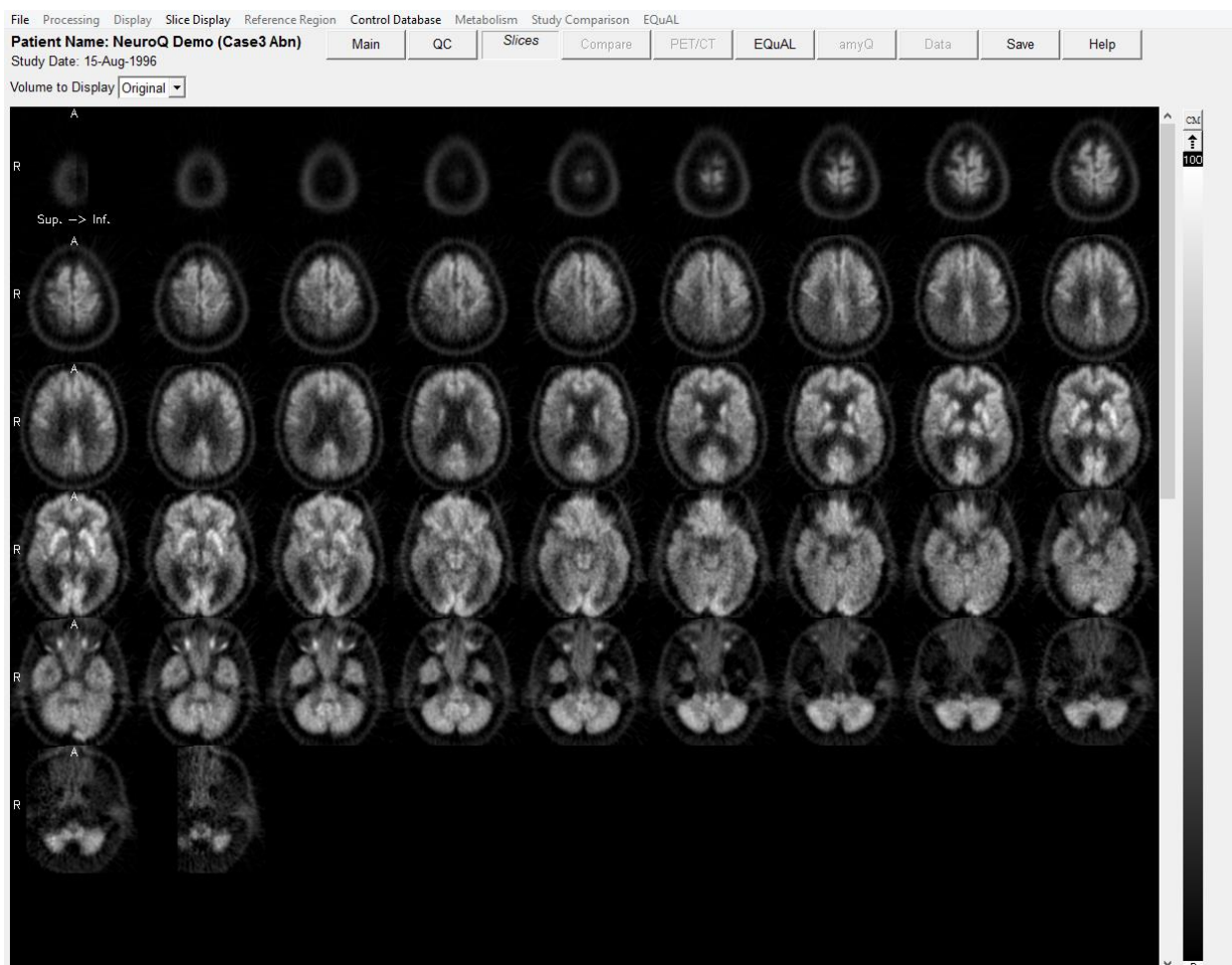


- a. “Show Color Scale” provides legend of the two-dimensional color coding. The # of Standard deviations is listed on the Y axis and the % below the mean normal value is listed on the X axis.

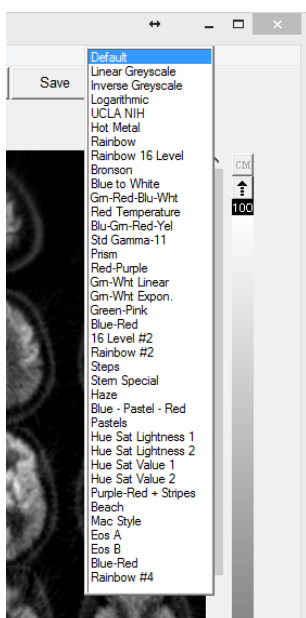


- b. “List Region Abbreviations” will list the various abbreviations used in the application along with their meaning, i.e. rAVC = right Associative Visual Cortex.
4. QC – The Quality Control screen allows the user to apply some preprocessing steps including setting axial planes limits, removing scalp activity, and performing a rigid registration. See Quality Control section above for a further description.

5. Slices – When the Slices button is selected it will bring up a new display window which initially will display the patients transaxial slices. From the Slice Display menu item you can also select to display the sagittal or coronal slices. This display is shown below.



The initial display will show the patients slices in inverted grey scale. An option is provided to display other translation tables by clicking on the CM (Color Map) button located above the color translation bar.

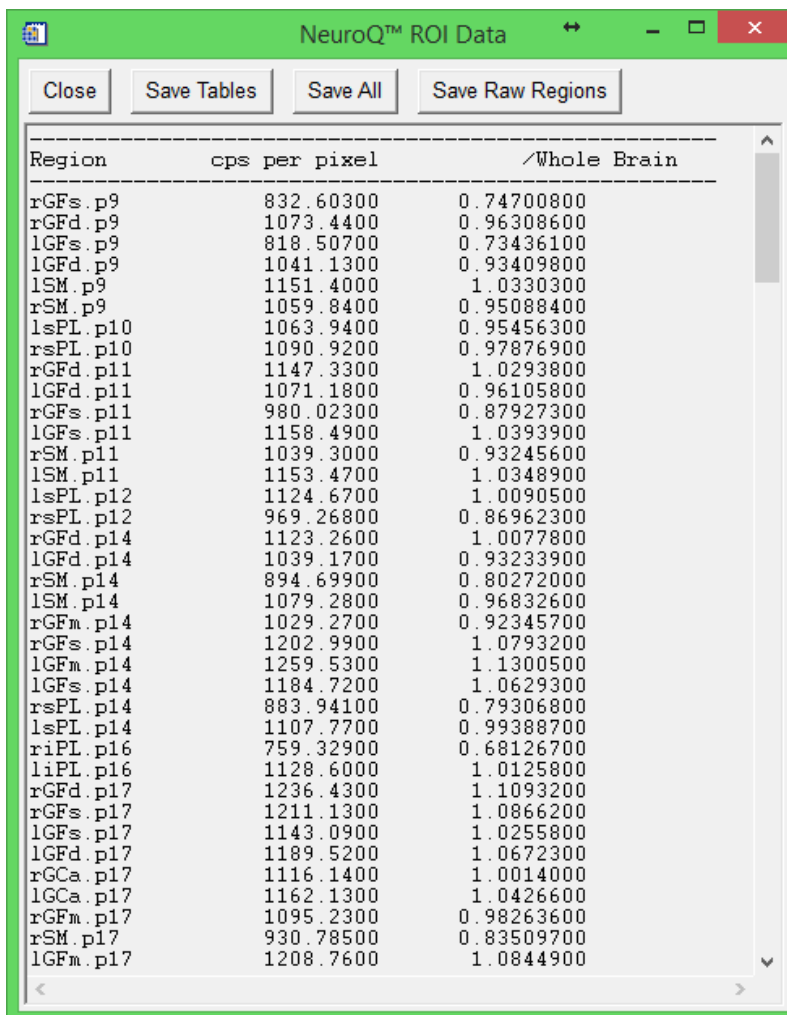


A table of color translation options will be displayed shown in table to the left. You can select any of these color tables and the display will change to reflect this color.

Changing up/low contrast – At the top of the color bar on the slices page is a value of 100 and at the bottom a value of 0. If you position your cursor over one of these numbers, click left, hold down, and move the value up or down you can adjust the contrast in the image. The upper value (100) when moved down will lower the upper value producing a brighter image. The lower value (0) when moved up will increase the lower value resulting in reducing counts in the image at the low end of the scale or darken the image.

You can display either the original images or images that have undergone registration from the Volume to Display drop down list. Note: to go back to the previous screen click on the Main button.

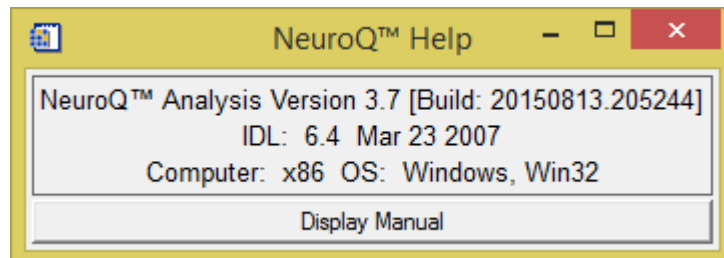
6. Compare – The compare screen allows the user to compare two studies from the same patient performed at different times. This analysis provides a Difference Image between the two studies showing which regions showed a change in hypo or hyper metabolic activity between the two studies. See the description of the Compare feature below.
7. PET/CT – The PET/CT screen allows the user to display both the PET and CT studies for the same patient – and fuse those two data sets using scroll bars. See the description of the PET/CT feature below.
8. EQuAL – The EQuAL analysis module is an optional feature that is helpful for evaluating temporal metabolic asymmetry. See the description of the EQuAL feature below for more information.
9. amyQ – The amyQ analysis module is an optional feature that allows for the investigation of amyloid uptake in the brain. See the description of the Amyloid Analysis feature below for more information.
10. Data – The data button will display the data screen which gives the “mean” (average number of counts per second per pixel in each ROI) for each of the 240 ROIs of the patient; “norm” refers to the “mean” normalized to the average of all pixels in all ROI’s (default). This screen is shown below. This data can be saved and then imported into another application like Excel for further analysis. You have the option to “Save Tables”, which are the tables presented on the Main screen for regions and clusters; “Save Raw Regions”, which saves the raw information for the ROIs; or “Save All”, which saves all of the available information.



The screenshot shows a window titled "NeuroQ™ ROI Data" with a green title bar. Below the title bar are four buttons: "Close", "Save Tables", "Save All", and "Save Raw Regions". The main area of the window contains a table with three columns: "Region", "cps per pixel", and "/Whole Brain". The table lists 240 ROIs, each with its corresponding counts per second per pixel and normalized value. The ROIs are listed in a specific order, starting with rGFs.p9 and ending with lGFm.p17.

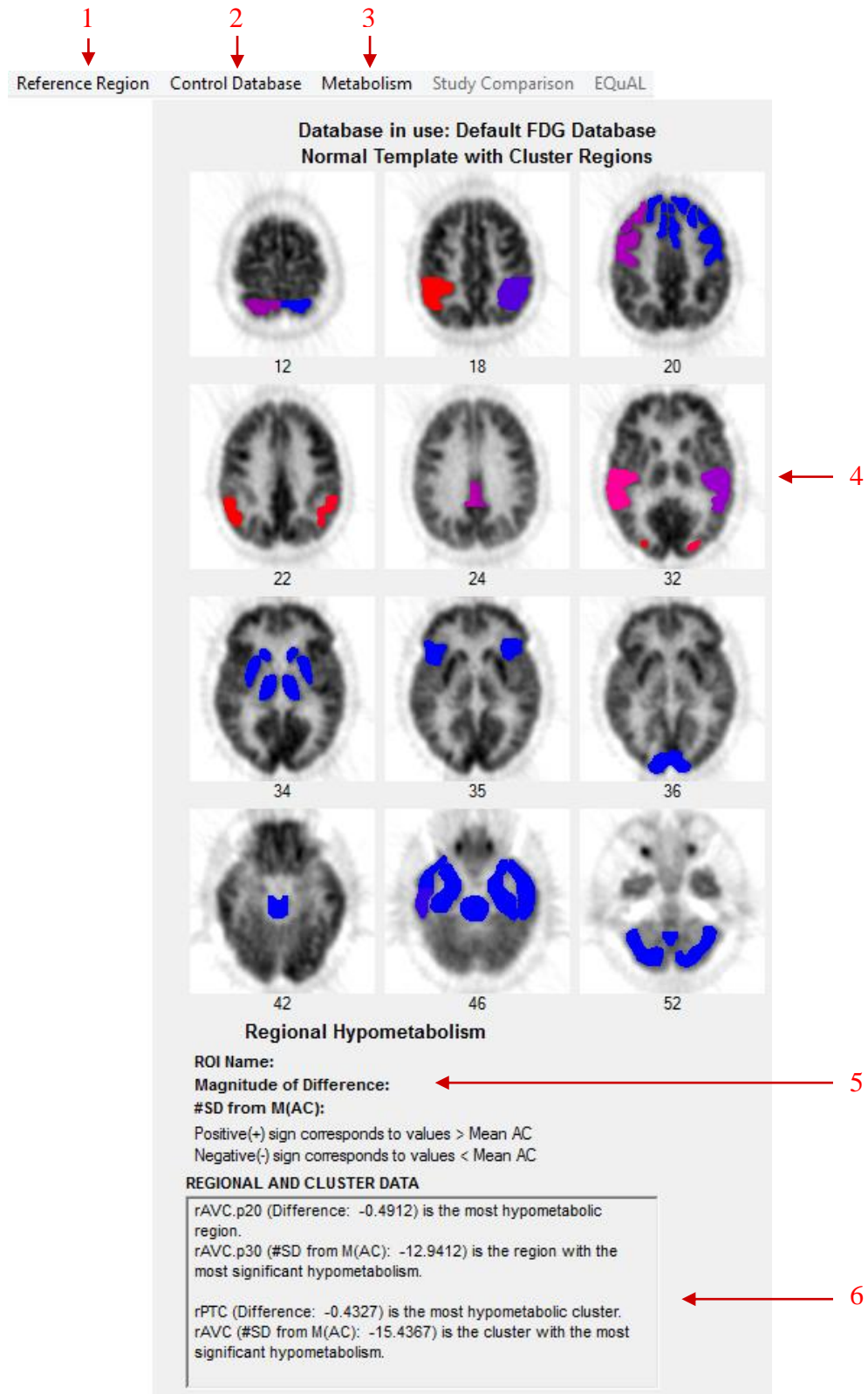
Region	cps per pixel	/Whole Brain
rGFs.p9	832.60300	0.74700800
rGFd.p9	1073.4400	0.96308600
lGFs.p9	818.50700	0.73436100
lGFd.p9	1041.1300	0.93409800
LSM.p9	1151.4000	1.0330300
rSM.p9	1059.8400	0.95088400
lsPL.p10	1063.9400	0.95456300
rsPL.p10	1090.9200	0.97876900
rGFd.p11	1147.3300	1.0293800
lGFd.p11	1071.1800	0.96105800
rGFs.p11	980.02300	0.87927300
lGFs.p11	1158.4900	1.0393900
rSM.p11	1039.3000	0.93245600
LSM.p11	1153.4700	1.0348900
lsPL.p12	1124.6700	1.0090500
rsPL.p12	969.26800	0.86962300
rGFd.p14	1123.2600	1.0077800
lGFd.p14	1039.1700	0.93233900
rSM.p14	894.69900	0.80272000
LSM.p14	1079.2800	0.96832600
rGFm.p14	1029.2700	0.92345700
rGFs.p14	1202.9900	1.0793200
lGFm.p14	1259.5300	1.1300500
lGFs.p14	1184.7200	1.0629300
rsPL.p14	883.94100	0.79306800
lsPL.p14	1107.7700	0.99388700
riPL.p16	759.32900	0.68126700
liPL.p16	1128.6000	1.0125800
rGFd.p17	1236.4300	1.1093200
rGFs.p17	1211.1300	1.0866200
lGFs.p17	1143.0900	1.0255800
lGFd.p17	1189.5200	1.0672300
rGCa.p17	1116.1400	1.0014000
lGCa.p17	1162.1300	1.0426600
rGFm.p17	1095.2300	0.98263600
rSM.p17	930.78500	0.83509700
lGFm.p17	1208.7600	1.0844900

11. Save – this option when selected will save all of the reformatted data and analysis into a single file called the NeuroQ™ Review File. This file can then be selected and the previous reformatted data and analysis will be displayed. This avoids having to reformat the data if it needs to be displayed at another time.
12. Help – this option will display the version number of NeuroQ™. The NeuroQ™ User's Manual can also be displayed in PDF format by clicking the Display Manual button.

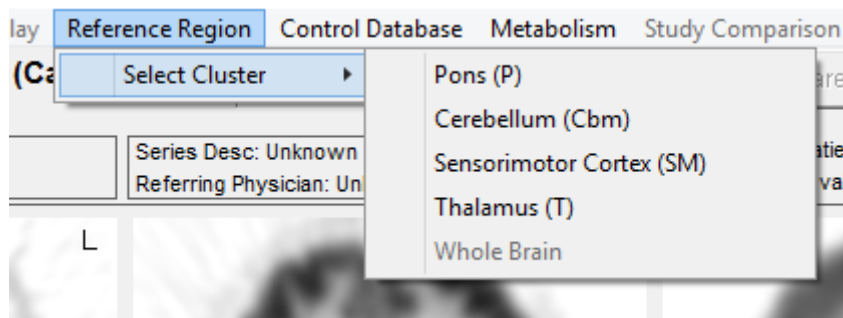


13. Patient Information – displays patient information.
14. Patient Brain Display – displays the original patient brain transaxial slices.
15. Left Plane Slider – controls the brain plane of the above patient brain display, the current plane number is displayed above the slider, slide to the left or right to access lower or higher planes respectively.
16. Normal Template Brain – based on an archetypal normal brain with no clinical or metabolic signs of neurodegenerative disease; ROI values for each plane are drawn in with a white outline.
17. Middle Plane Slider - controls the brain plane of the normal brain display and the reformatted patient brain display at right; the current plane number is displayed above the slider, slide to the left or right to access lower or higher planes respectively, simultaneously for both displays.
18. Reformatted Patient Brain – brain is based on specified number of reiterations of the original patient brain scan; this display only appears after reiteration of brain images. All abnormal regions will be displayed in a two-dimensional coded color scale, click on the Help button for color coding explanation.
19. Table of Abnormal Regions – displays all regions having internally normalized region of interest (ROI) radiotracer uptake values falling more than 1.65 standard deviations below the mean value (in the Hypometabolic operation) and more than 1.65 standard deviations above the mean value (in the Hypermetabolic operation) for a symptomatic control group; regions are displayed in abbreviated form with the plane number after the “.p”; the last row of the table gives a total of the “Pt-M(AC)” and “#SD from M(AC)” columns. By clicking on a hypometabolic region in the reformatted patient brain image, the name of the region will be displayed above the region table and the row of the region that was selected will be highlighted in the region table.
20. Table of Cluster Values – the ROI cluster value is based on the average of the represented region across all planes where it is assessed. By clicking on one of the 47 cluster regions in the cluster screen, the name of the region will be displayed in the table below the cluster screen and the row of the region that was selected will be highlighted in the cluster table.

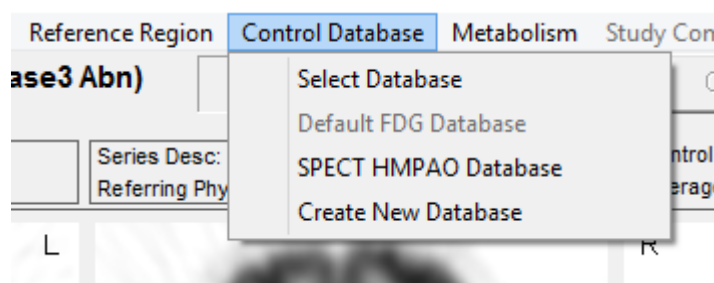
NeuroQ™ Display Screen (Right Side)



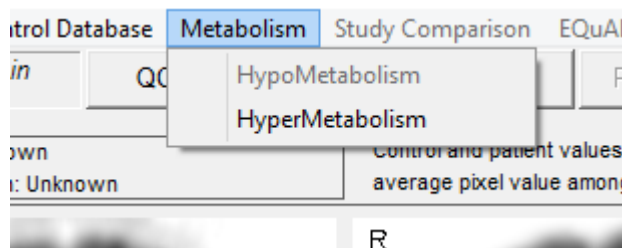
1. Reference Region Menu – user can select which cluster (among “Pons”, “Cerebellum”, “Sensorimotor”, “Thalamus”, or “Whole Brain”) to base the normalization of the regions on. NOTE: the default normalization is based on the whole brain.



2. Control Database – user can use this feature to create their own database to use within the NeuroQ™ application. See description of this feature below.

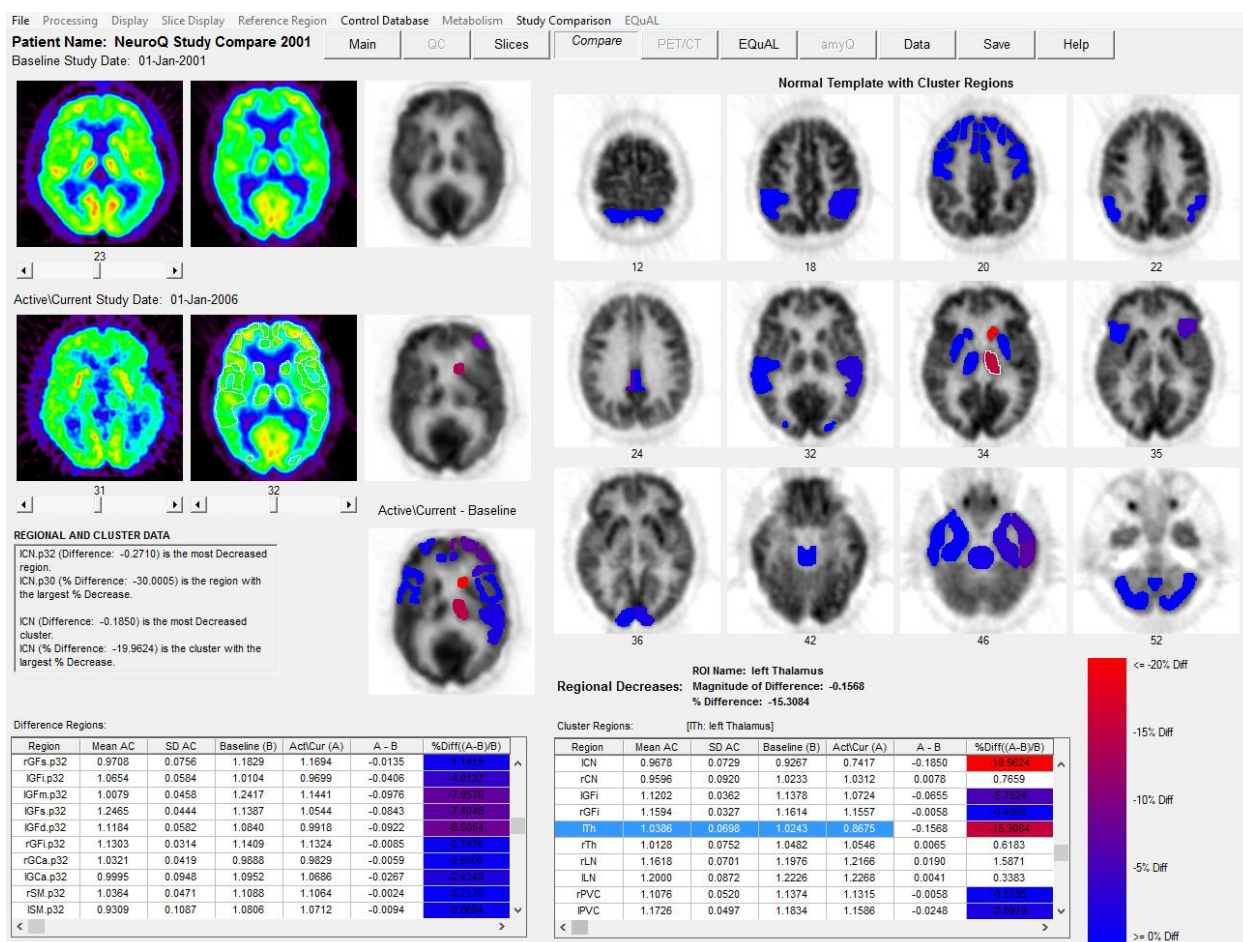


3. Metabolism Menu – “Hypometabolism” displays the most hypometabolic regions and performs calculations accordingly, “Hypermetabolism” displays the most hypermetabolic regions and performs calculations accordingly, NOTE: default is “Hypometabolism”.



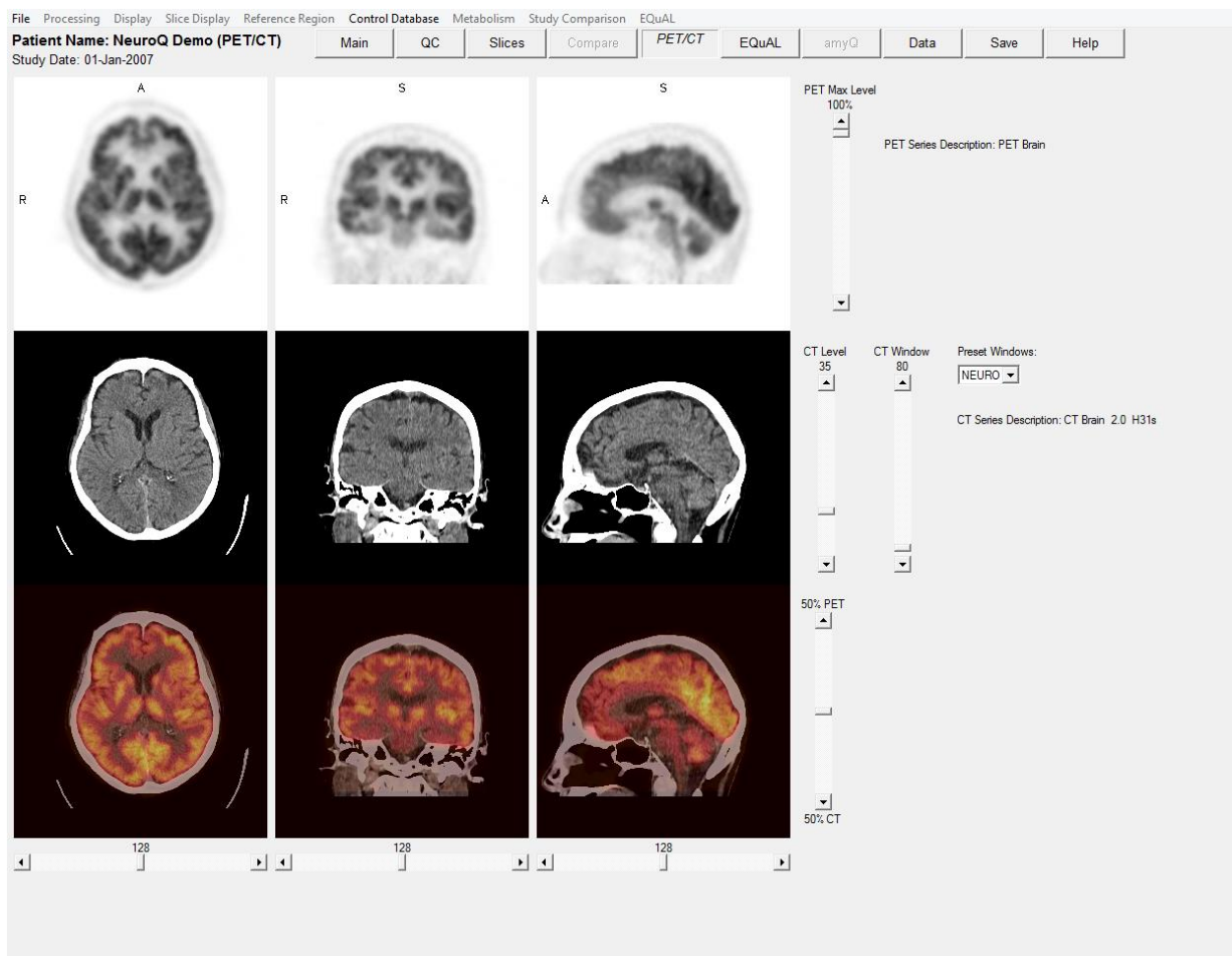
4. Brain Plane Displays – includes schematic display of each of the 47 ROI clusters, shown at the normal template planes numbered below each image. Refer to the “Show Color Scale” description for color coding explanation. Clicking on a ROI causes the full name and numerical characterization of that region to appear in the Data Display area.
5. Data Display – displays information based on the last ROI cluster the user clicked on.
6. Regional and Cluster Data – gives the most hypometabolic or hypermetabolic and most significant regions and clusters.

NeuroQ™ Compare Display Screen



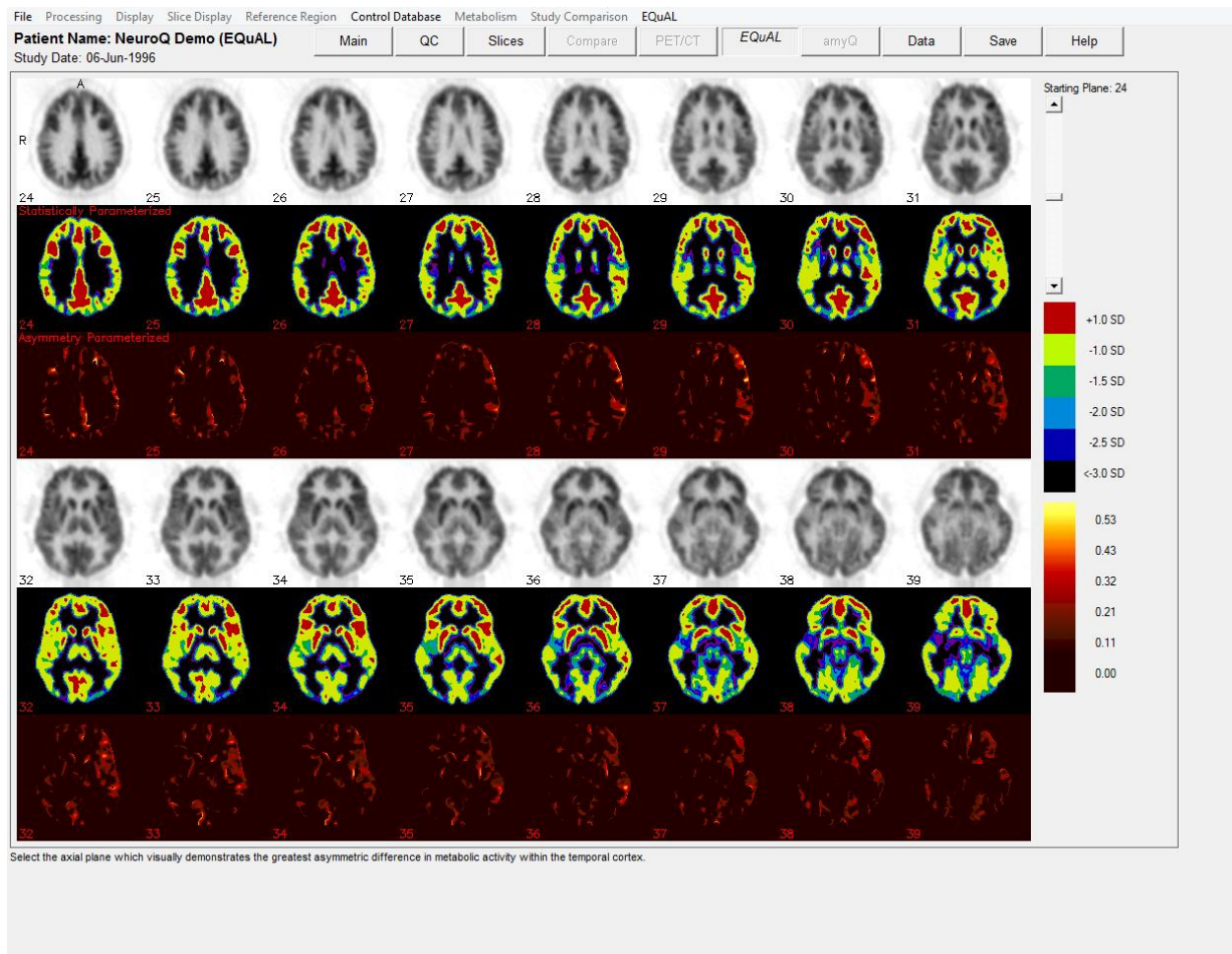
The NeuroQ™ Compare Screen is enabled by selecting the two studies from the MCP screen and clicking on the launch button. Once NeuroQ™ is launched it will show the most recent study in the main NeuroQ™ screen. Click on the Compare button and the Compare display screen will be shown. The oldest study is displayed in the top row, the most recent in the middle row, and the difference image is displayed in the bottom image to the right. Use the middle slider bar in the middle row to step through the planes. All images with the exception of the patient's images in the left hand column will move when the slider bar is moved left or right. The difference image shows the regions in which there is at least a 1 standard deviation difference between the original and recent study. This analysis is helpful to monitor the progression of dementia over a period of time.

NeuroQ™ PET/CT DISPLAY SCREEN



The PET/CT display allows for displaying both the PET and CT brain images from the same patient. The PET brain images are contained in the top row. The PET brain images brightness can be changed by sliding the PET Max Level slider up or down. The CT images are contained in the middle row. The CT brain images window level can be changed by manipulating the sliders for CT Level and CT Window up or down. The user also has the option picking preset windows for Neuro or Bone in the Preset Windows drop down box. The bottom row contains the fused images. The PET/CT slider bar allows the user to display only the PET (slider all the way up), only the CT (slider all the way down), or fused (slider in the middle). Various levels of fusion can be displayed by moving the slider up or down. Triangulation is enabled on the PET, CT and Fused images by clicking left on any image and it will show you the plane for that location on the other two images.

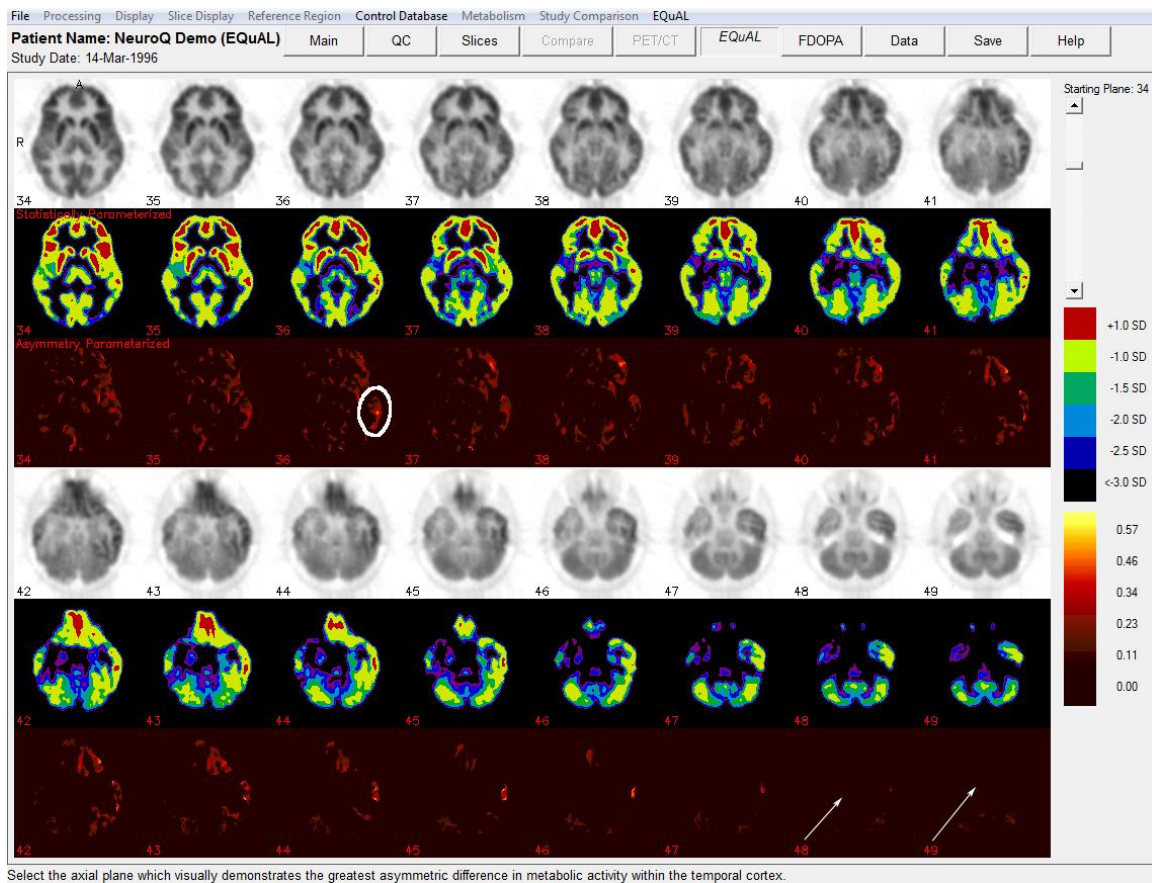
EQuAL™ Analysis



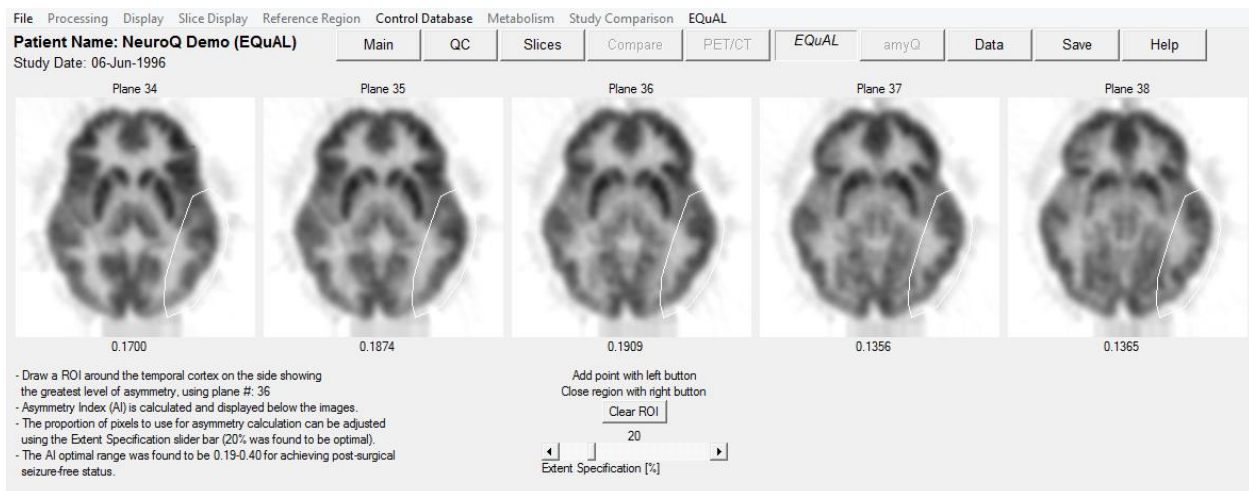
The Extent-Specified Quantified Asymmetry-of-Lobe (EQuAL) Analysis will be included with NeuroQ 3.0. This program is useful for assessing maximal temporal asymmetry over a specified proportion of the temporal lobe which may help to predict whether patients will likely be free of seizures during the years after neurosurgical resection of epileptogenic tissue.

To use EQuAL, select the patient desired and launch NeuroQ™ from MCP. Process the study as you would normally. Once NeuroQ™ is finished reformatting the data, select the EQuAL tab from the top of the screen. Select the image that the user feels best exemplifies the asymmetrical defect. Use the slider bar on the right hand side of the screen to see all slices. See example above.

Once an image has been selected, the EQuAL ROI screen will appear. Follow the on screen instructions to get the Asymmetry Index (AI).



EQUAL Processing – When processing an EQUAL study you are going to select an image from the above display and that is the image where an ROI over the temporal lobe will be drawn, as shown in the display below. When selecting that image you want to use the Assymetry Parameterized (AP) row of images (3rd and 6th row, images displayed in red) to select this image. You must see activity in the AP images in order for this analysis to provide valid data. A proper image would be image 36 shown with the circle drawn over the temporal lobe (remember you will be drawing your ROI on the gray scale images shown below). If you select images without activity (images 48 or 49 shown with arrows) then the values calculated will be 0. If the EQUAL value is 0, with the default extent specification of 20%, then first insure that there is visually evident bilateral asymmetry in the part of the brain over which the ROI has been drawn, and second, that the ROI has been placed on the side that has higher activity. If these 2 conditions have been met, then a 0 value indicates that fewer than 20% of the pixels in this ROI contribute to the observed asymmetry. To obtain a non-zero EQUAL value, try decreasing the extent specification to less than 20%.

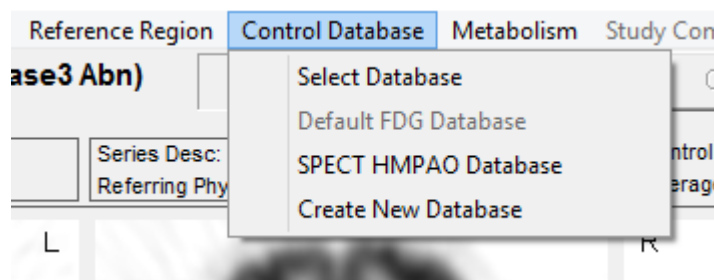


The results of this study were by Lin et. al from the Department of Molecular and Medical Pharmacology, David Geffen School of Medicine, UCLA Los Angeles was published in the May issue of the Journal of Nuclear Medicine:

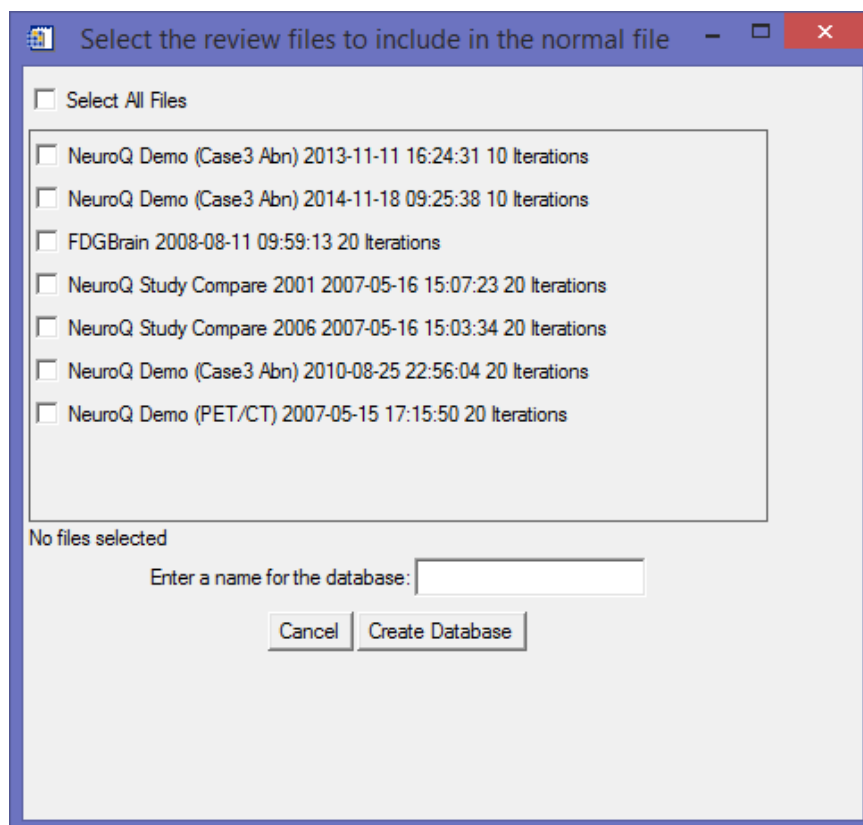
Tina W. Lin, Michelle A. Kung de Aburto, Magnus Dahlbom, Lynn L. Huang, Michael M. Marvi, Michael Tang, Johannes Czernin, Michael E. Phelps, and Daniel H.S. Silverman. Predicting Seizure-Free Status for Temporal Lobe Epilepsy Patients Undergoing Surgery: Prognostic Value of Quantifying Maximal Metabolic Asymmetry Extending over a Specified Proportion of the Temporal Lobe. J Nucl Med. 2007 48(5): 776-782.

Control Database

NeuroQ™ provides the user with the ability to generate their own normal database to use within the application.



- Select Database – allows the user to select a database that was previously created by the user.
- Default FDG Database – sets the PET FDG database that was created and validated by UCLA.
- SPECT HMPAO Database – sets the SPECT HMPAO database that was created and validated by UCLA.
- Create New Database – This allows the user to create their own normal database. The first step would be to process all of the normal studies through NeuroQ™ and save them as NeuroQ™ review files. These review files will have an extension .nrq. These NeuroQ™ review files then need to be all placed in the same folder on the disk. After selecting Create New Database you will have to browse to the folder containing all of normal NeuroQ™ Review files. After selecting that folder the following dialog screen is displayed.



Select all the files you want included in the database, enter the name for the database file in the box, and then click on the Create DB button to generate the normal database. This normal file can then be selected and used as the normal database in NeuroQ™.

IMPORTANT: GENERATION OF A NORMAL DATABASE TO BE USED IN THE NEUROQ™ APPLICATION IS THE SOLE RESPONSIBILITY OF THE USER. SYNERMED OR UCLA HAVE ONLY VALIDATED THE PET FDG NORMAL DATABASE PROVIDED WITH THE APPLICATION. SYNERMED AND UCLA HAVE NO RESPONSIBILITY OR ARE LIABLE FOR ANY RESULTS PROVIDED BY NEUROQ™ THAT ARE GENERATED BY ANY OTHER DATABASE GENERATED BY USERS OF THE APPLICATION USING THIS TOOL.

Amyloid Overview, Processing, and Display

Introduction

The FDA approved the florbetapir F18 radiopharmaceutical agent (Amyvid, Eli Lilly) on April 6, 2012. Florbetapir binds to amyloid aggregates in the brain, and the florbetapir PET image is used to estimate the density of β -amyloid neuritic plaque (17).

Image Registration and Development

The amyloid image registration is performed in two parts. First the subject's brain is aligned to the reference brain using a rigid registration (i.e., translations in x, y and z, and rotations around the three axes). The maximization of the mutual information is the metric used to determine the best registration parameter. The result from the rigid registration is then passed onto a B-spline based deformable image registration algorithm, which also attempts to maximize the mutual information between the two image volumes to determine the best registration. For computational efficiency and faster convergence, the deformable registration is performed in two parts. First, using a coarse grid, which is followed by a registration using a finer and more precise grid.

In addition to the development of the registration software, a template or reference amyloid brain was constructed, which is used when analyzing individual amyloid images. For this, 20 with low uptake of amyloid in PET studies were selected. Each one of these subjects also had anatomical images (i.e., T1 weighted MRI). Using the high-resolution anatomical imaging for registration allows for a more accurate registration compared to a PET-to-PET registration. The subject's PET was first registered to the MRI. Then the MRI was registered to the reference brain template, already defined in NeuroQ for the analysis of FDG brain images. The registration performed was the same as described above (i.e., rigid registration followed by a deformable registration). Once the transformation of the subject's MRI to the reference template was found, the same transformation was applied to the subject's amyloid PET image.

This process was repeated for all 20 low amyloid uptake subjects. Each registered PET study was then normalized to the average uptake in cerebellum. The amyloid reference brain was finally constructed by taking the average of all 20 registered and normalized brains. In the analysis of a subject's amyloid images, the PET images are first registered to the reference amyloid brain, using the registration method described.

Following the registration, the average uptake in the cortex and in cerebellum is determined. These regions are a subset of the regions already defined in the brain template in NeuroQ. The ratio of the average cortex uptake to the average uptake in cerebellum is then calculated. This ratio value has been integrated into the current NeuroQ application (18) and displayed together with a visualization of the regions used in the determination of the uptake in cortex and cerebellum, overlaid on the subjects registered brain (Figure 1).

PLEASE NOTE: The ratios of overall cortex to cerebellum is provided as a general index of the magnitude of cortical tracer retention only. There are no recognized or intended threshold values for drawing specific conclusions about an individual patient's diagnosis or prognosis.

The relative patterns of distribution of tracer retention within the cortex, as illustrated by the color-coded displays of regional distribution, are intended to be used as an adjunct to visual analysis, which the user can employ for the purpose of indicating specific regions upon which extra attention may be focused in carrying out visual interpretations.

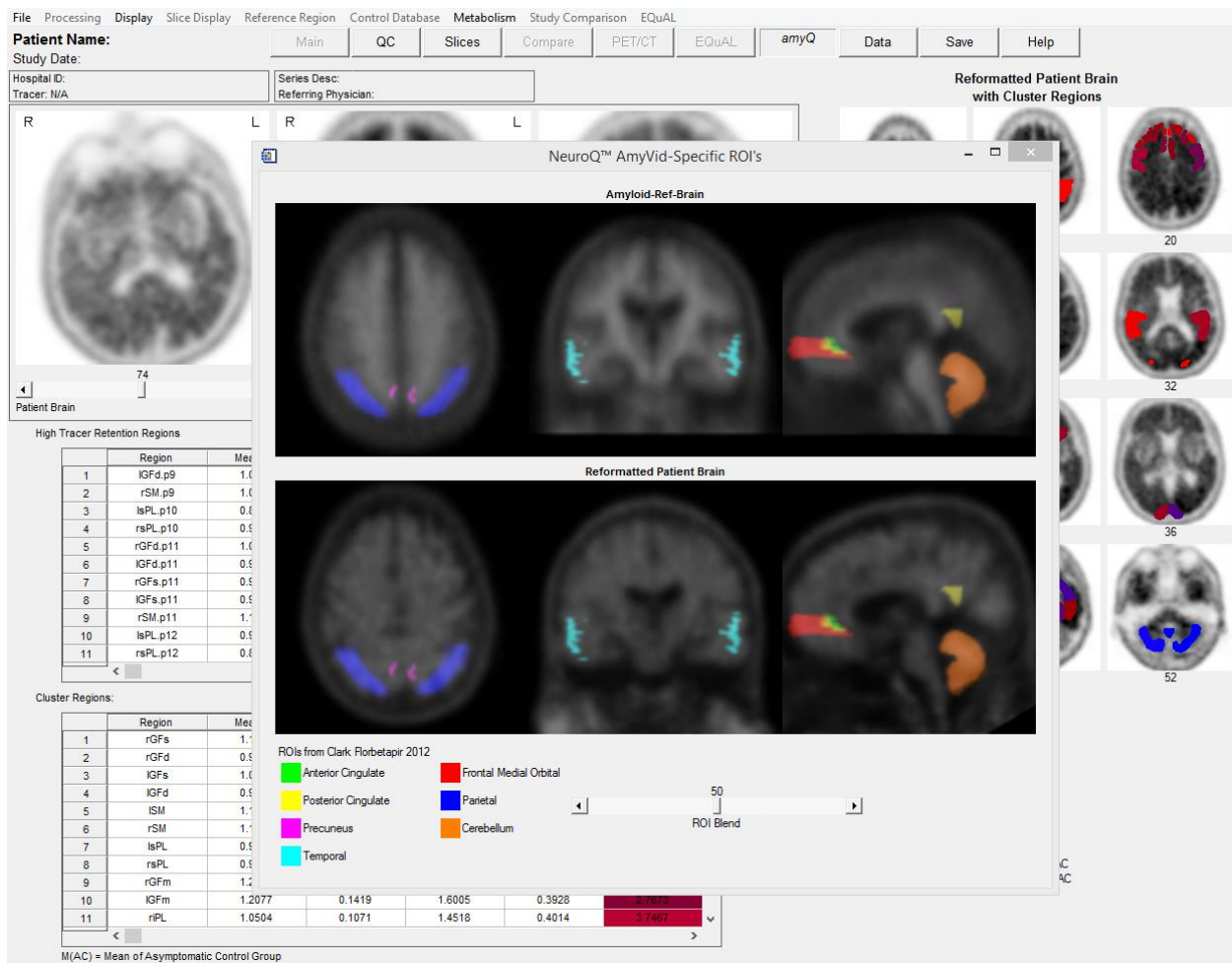


Figure 1 - Amyloid Analysis Display Output. The display output of the amyloid analysis in the NeuroQ application is shown. The regions representing the cortex (white matter) are shown in shades of red/purple and the cerebellum (gray matter) are shown in blue. The ratio between the cortex and cerebellum is calculated and shown on the display output, in this case the ratio was calculated as 1.656. Clicking on the Show ROIs button will bring up a display of the ROIs used in this analysis.

Validation

The results of the validation conducted for the amyloid study using this technique demonstrated the following with respect to the cortex vs cerebellum average ratio: low amyloid uptake (n=80), mean = 0.988 ± 0.058 and high amyloid uptake (n=39), mean = 1.504 ± 0.192 . Using a ratio cutoff of 1.10 the results for detecting high levels of amyloid in the high amyloid uptake group was 20/20 and for detecting low levels of amyloid in the low amyloid uptake group was 19/20.

Amyloid processing

The steps for processing an amyloid study are listed below.

1. Select the amyloid study from the MCP screen and launch into the NeuroQ application.
2. Click on the amyQ button to initiate the processing of the amyloid study which is all performed automatically.
3. Once the processing is completed the amyloid analysis window will be displayed showing the patients results (Fig 1).

SPECT Overview, Processing and Display

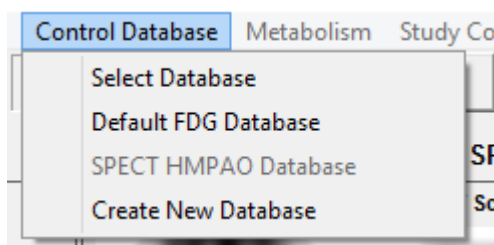
Introduction

The NeuroQ application can also be used to process HMPAO SPECT brain studies.

Image Processing

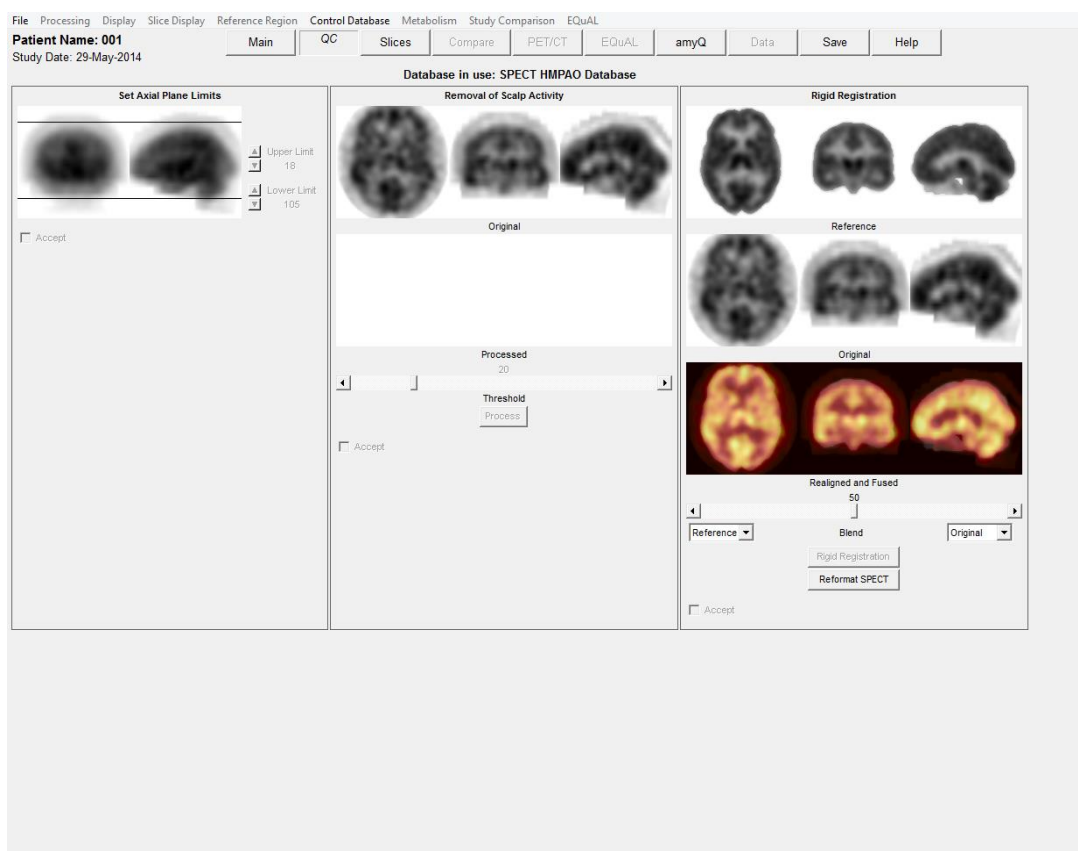
1. Database in Use

The database used for analysis of SPECT studies should be the SPECT HMPAO Database. The NeuroQ program attempts to determine if this is a SPECT study when you first launch NeuroQ with a SPECT study. If this database is not displayed as the Database in use then you will need to go to Control Database menu item and select the proper normal database for the patient.



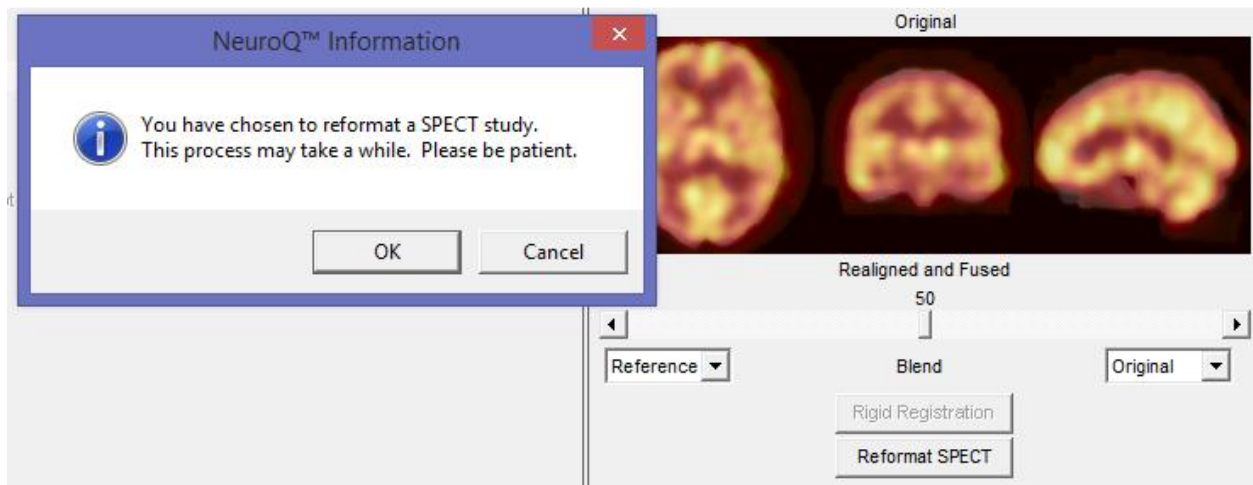
2. Quality Control Screen

The first screen displayed is the Quality Control Screen. The processing on this screen is not required for SPECT, all of this processing is performed automatically so each of these sections are greyed out with the exception of the Reformat SPECT button.



3. Reformatting

Click on the Reformat SPECT button and the following notification screen will be displayed letting you know that 10 iterations will be used for the reformatting. Next select the OK button to start the reformatting process.



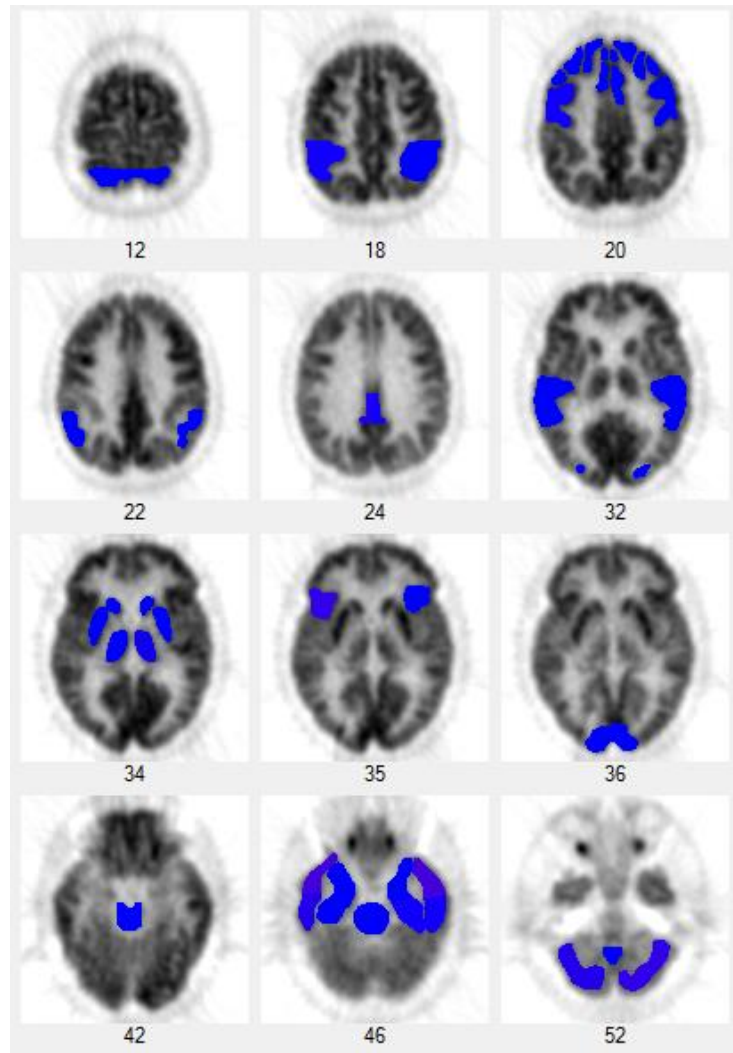
4. Further Processing

The remainder of the processing and display is the same for FDG and SPECT and this is described above in the section titled NeuroQ Analysis Screen on pages 10-16.

Description of Example Patient's

Demo, Case1 – Normal Case

This case demonstrates the quantitative output produced by NeuroQ™ when it is used to analyze a normal study. The blue areas within the cluster regions indicate that the metabolic uptake was all above the normal limit of 1.65 standard deviation. Mr. E was 71 years old when he was first referred to the UCLA Ahmanson.



Demo, Case2 – Mildly Abnormal

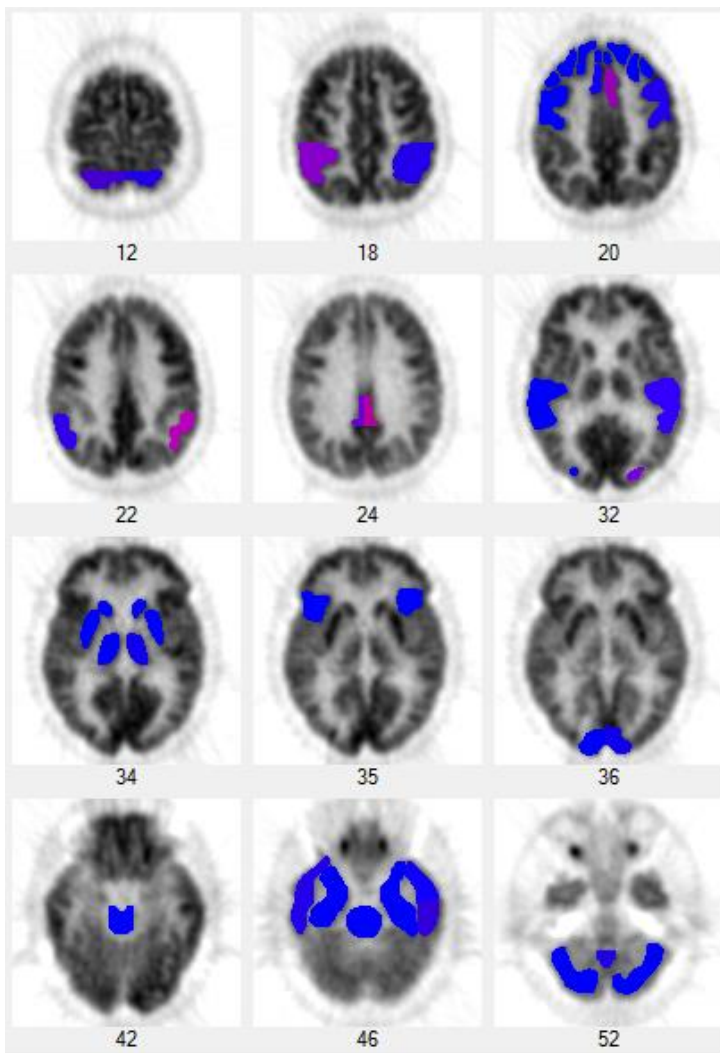
Patient History

Mr. E was 71 years old when he was first referred to the UCLA Ahmanson Biological Imaging Division in December 2001 with concern for worsening memory. He reported that he always had a poor memory, but that over the preceding seven years, he began to notice his memory getting worse, including forgetting where he put his keys and forgetting names or faces. Mr. E had worked as a physicist for 25 years and taught physics at the University-level for the following 20 years. He reported no psychiatric hospitalizations, illness, or medication use. Mr. E had no significant medical history, including hospitalizations or illness, with the exception of prostate surgery for benign enlargement. He did not use tobacco, alcohol or other drugs and had no history of such use. His physical examination, neurologic exam and blood laboratory values (including TSH, B12, CBC, ALT and Cr) were within normal limits.

Mr. E underwent comprehensive neuropsychologic testing at the time of his first visit in 2001, and was found to be cognitively normal for his age.

Why was a PET scan obtained at this time?

This patient is seeking a diagnosis for his chief complaint, a convincing history of cognitive decline. His symptoms are unexplained by any factors identified in his history, physical or laboratory work-up. Moreover, for patients possessing his apparent high level of pre-morbid intellectual ability and education, it is common for loss of cognitive ability to be experienced, while still being able to perform at levels considered to be within the normal ranges of standard neuropsychological tests.



PET Interpretation

The scans from 2001 and 2004 each reveal mild parietal/temporal hypometabolism, more pronounced on the left (right side of image). NeuroQ™ analysis identifies mild abnormalities (purple to red shades) in parietal/temporal and posterior cingulate regions, with well-preserved metabolism in other regions (blue shades)... a pattern very suggestive of early Alzheimer's type changes occurring in this patient's brain.

The pattern of cerebral metabolism in 2004 has slightly changed since 2001. Visually, there appears to be slight interim worsening of parietal/temporal hypometabolism. [Show combined figure with arrows, on slide 3, here.] That impression is bolstered by the NeuroQ™ analysis, which shows in its plane 22 image the left parietotemporal cortex advancing to a near-red shade (12% and 4 standard deviations below normal) in 2004, from the purple shade (9% and 3 SD below normal) seen in 2001.

Case Summary

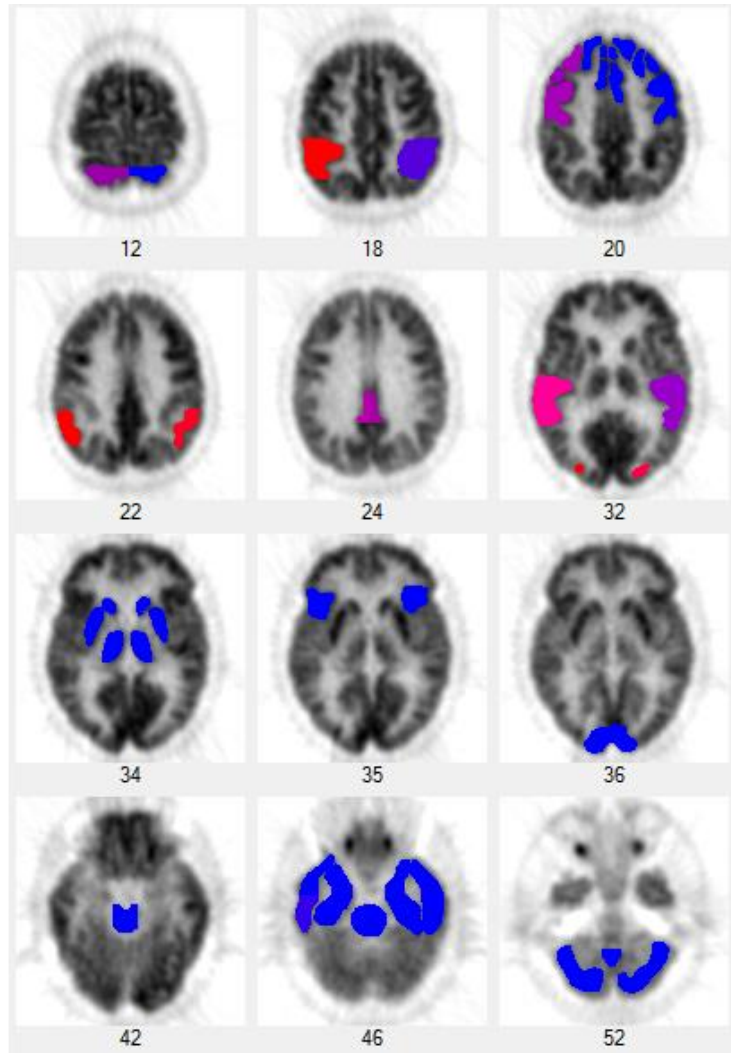
To summarize, at a time when conventional clinical evaluation was not sufficiently sensitive to document cognitive abnormality in this 71 year old physicist reporting memory problems, PET was already documentably (mildly) abnormal, both by visual and quantitative analyses. From 2001 to 2004, neuropsychologic performance with respect to immediate and delayed memory for word associations, contextual information, rote list learning, and complex visual stimuli declined across testing sessions, indicating "significant cognitive deterioration" within those abilities, according to the neuropsychologist. By 2004, Mr. E's performance met criteria for "Mild Cognitive Impairment,"

performing between one and two standard deviations below the mean established for his same age peers on at least 50% of the memory tasks. The combination of this clinical progression, with the posterior-predominant pattern of hypometabolism affecting especially parietal/temporal cortex is most consistent with the presence of incipient Alzheimer's disease. Armed with the FDG-PET information, his managing physician prescribed an anti-Alzheimer's combination regimen including both donepezil and memantine in advance of the second neuropsychologic testing session. On his current regimen, he continues to achieve 30/30 on the Mini Mental State Examination (MMSE).

Demo, Case3 – Severely Abnormal

Patient History

Mr. F was 63 years old when he underwent FDG-PET in August 1996 for symptoms of decreased memory, language and visual skills. The cognitive decline had been noted for at least 2 years, as had been sensory and motor deficits of his left upper extremity. Mr. F's past medical history was positive for pyelonephritis, prostatitis, and prostate surgery for benign enlargement. The patient had a history of heavy alcohol use in the past, but had discontinued drinking, and did not use tobacco or other drugs nor have a history of such use. He was a lawyer, as was his wife, and they had two small children. His physical examination, other than his neurologic exam was normal. His neurologist noted upon exam that the patient got two of three items correct regarding orientation and three of four words remembered correctly at 3 minutes, and that he had marked apraxia of the upper extremities with left worse than right, plus "mild Parkinsonism with a mask face"; cranial nerves were intact and reflexes were normal. Blood laboratory tests obtained one month prior to PET were normal, including CBC, electrolytes, BUN, creatinine, glucose, calcium, cholesterol, and liver enzymes; VDRL and TSH tests obtained the following year were also normal. The neurologist following Mr. F, an internationally recognized expert on dementia and Director of a university-based Alzheimer's Disease Center, diagnosed him with corticobasal degeneration and depression, for which he was treated with the antidepressant sertraline.



Structural Neuroimaging

1992 Brain MRI revealed "mild enlargement of the lateral ventricles... otherwise unremarkable."

1994 Brain MRI with and without contrast revealed "progression of cerebral atrophy."

1995 Brain MRI revealed "moderate generalized cerebral atrophy which is not significantly changed when compared to the scan of 1994. The scan is otherwise within normal limits."

1996 Brain MRI with and without contrast revealed "stable appearance of cerebral cortical atrophy."

1997 Head CT revealed "cerebral atrophy but is otherwise negative."

Why should the patient get a PET scan at this point in his evaluation?

Mr. F has documented cognitive decline and motor symptoms noted on neurologic examination. The symptoms are unexplained by his general history, physical examination, laboratory screen and structural neuroimaging tests, which are largely unremarkable. Although he was evaluated by a prominent dementia expert who did not suspect Alzheimer's disease, there are no tests (short of brain biopsy) documented to be as accurate as FDG-PET in the

identification of Alzheimer's disease that the neurologist did, nor could do, to exclude the possibility of that now-treatable condition.

Clinical Follow-up

Mr. F. continued to progressively deteriorate with respect to cognitive and motor symptoms, also developing a seizure disorder before his death that proved resistant to medical therapy. An autopsy was performed in 2000 at the Alzheimer's Disease Center for which the patient's neurologist was Director, and the final diagnosis was "Alzheimer disease, [Braak and Braak Stage VI, CERAD definite]" with abundant neurofibrillary tangles in the hippocampus, entorhinal cortex and neocortex, as well as amyloid-beta(1-42)-staining plaques prominent throughout all areas of hippocampus, entorhinal cortex and neocortex. (Synuclein staining to check for the presence of Lewy bodies was not performed.)

Case Summary

To summarize, by the time of this PET scan, Mr. F. had undergone extensive evaluation of his cognitive and motor symptoms, including history and physical examinations by his internist, neurologic examination by a dementia expert, laboratory screening, as well as multiple brain MRI studies, two of them including contrast, and subsequently a head CT. The clinical examination led to diagnoses of corticobasal degeneration and depression, the laboratory screen was negative, and the structural imaging studies demonstrated only atrophy.

None of the above studies pointed to the presence of Alzheimer's disease, and the patient correspondingly received no treatment specific to that diagnosis. The presence of Alzheimer's disease, however, was clearly evident on both PET and autopsy examinations. PET also revealed profound hypometabolism of associative visual cortex (quantified by NeuroQ™ as falling as much as 12 standard deviations below normal metabolic levels) suggesting Lewy body involvement, which could also help to explain the prominence of the patient's central motor symptoms.

References For Case Study 2

Journal Articles

- Knopman DS, DeKosky ST, Cummings JL, Chui H, Corey-Bloom J, Relkin N, Small GW, Miller B, Stevens JC (2001) Practice parameter: diagnosis of dementia (an evidence-based review). Report of the Quality Standards Subcommittee of the American Academy of Neurology. *Neurology*. 56:1143-1153.
- Hoffman JM, Welsh-Bohmer KA, Hanson M, Crain B, Hulette C, Earl N, Coleman RE (2000) FDG PET imaging in patients with pathologically verified dementia. *J Nucl Med*. 41:1920-1928.
- Silverman DHS, Small GW, Chang CY, Lu CS, Kung De Aburto MA, Chen W, Czernin J, Rapoport SI, Pietrini P, Alexander GE, Schapiro MB, Jagust WJ, Hoffman JM, Welsh-Bohmer KA, Alavi A, Clark CM, Salmon E, de Leon MJ, Mielke R, Cummings JL, Kowell AP, Gambhir SS, Hoh CK, Phelps ME. (2001) Positron emission tomography in evaluation of dementia: regional brain metabolism and long-term outcome. *JAMA* 286:2120-27.
- Silverman DHS, Truong CT, Kim SK, Chang CY, Chen W, Kowell AP, Cummings JL, Czernin J, Small GW, Phelps ME. (2003) Prognostic value of regional cerebral metabolism in patients undergoing dementia evaluation: comparison to a quantifying parameter of subsequent cognitive performance and to prognostic assessment without PET. *Molec Gen and Metab*: 80:350-355.
- Chang CY and Silverman DHS (2004) Accuracy of early diagnosis and its impact upon the management and course of Alzheimer's disease. *Expert Rev of Molec Diagnostics* 4(1):63-69.
- Silverman DHS (2004) Brain F-18-FDG PET in the diagnosis of neurodegenerative dementias: comparison with perfusion SPECT and with clinical evaluations lacking nuclear imaging. *J Nucl Med*. 45:594-607.
- Silverman DHS and Alavi A (2005) PET imaging in the assessment of normal and impaired cognitive function. *Radiologic Clin North Am*, Saunders, Philadelphia, 43:67-77.

References For Case Study 3

- Chang CY and Silverman DHS (2004) Accuracy of early diagnosis and its impact upon the management and course of Alzheimer's disease. *Expert Rev of Molec Diagnostics* 4(1):63-69.
- Imamura, T., K. Ishii, M. Sasaki, et al., Regional cerebral glucose metabolism in dementia with Lewy bodies and AD: a comparative study using positron emission tomography. *Neurosci. Lett*. 1997;235:49-52.
- Ishii K, Yamaji S, Kitgaki H, et al. Regional cerebral blood flow difference between dementia with Lewy bodies and AD. *Neurology* 1999, 53: 413-416.
- Knopman DS, DeKosky ST, Cummings JL, Chui H, Corey-Bloom J, Relkin N, Small GW, Miller B, Stevens JC: Practice parameter: diagnosis of dementia (an evidence-based review). Report of the Quality Standards Subcommittee of the American Academy of Neurology. *Neurology*. 2001; 56:1143-1153.
- Minoshima S, Giordani B, Berent S, Frey K, Foster NL, Kuhl DE. Metabolic reduction in the posterior cingulate cortex in very early AD. *Ann Neurol*. 1997;42:85-94.
- Silverman DHS (2004) Brain F-18-FDG PET in the diagnosis of neurodegenerative dementias: comparison with perfusion SPECT and with clinical evaluations lacking nuclear imaging. *J Nucl Med*. 45:594-607.
- Silverman DHS and Devous MD (2004) PET and SPECT imaging in evaluating Alzheimer's disease and related dementia. In *Nuclear Medicine in Clinical Diagnosis and Treatment*, 3rd edition, PJ Ell and SS Gambhir, eds., Churchill Livingstone, Elsevier.

Recent Textbooks

- Silverman DHS and Melega WP (2004) Molecular imaging of biological processes with PET: evaluating biologic bases of cerebral function. In *PET: Molecular Imaging and Its Biological Applications* ME Phelps, ed., Springer-Verlag, New York, pp. 509-583.
- Silverman DHS and Devous MD (2004) PET and SPECT imaging in evaluating Alzheimer's disease and related dementia. In *Nuclear Medicine in Clinical Diagnosis and Treatment*, 3rd edition, PJ Ell and SS Gambhir, eds., Churchill Livingstone, Elsevier.
- Silverman DHS, Strommer JL, Marseille DM, Gambhir SS (2004) PET Brain Atlas. In *Nuclear Medicine in Clinical Diagnosis and Treatment*, 3rd edition, PJ Ell and SS Gambhir, eds., Churchill Livingstone, Elsevier.

References Related to NeuroQ™ Development

1. Silverman DHS and Melega WP, Molecular imaging of biological processes with PET: evaluating biologic bases of cerebral function, in *PET: Molecular Imaging and Its Biological Applications*, pp. 509-583, Springer-Verlag, New York, 2004.
2. Minoshima, Satoshi, Frey, Kirk A., Koeppe, Robert A., Foster, Norman L., and Kuhl, David E., A diagnostic approach in Alzheimer's disease using three-dimensional stereotactic surface projections of fluorine-18-FDG PET. *Journal of Nuclear Medicine*, **36**: 1238-1248, 1995.
3. Tai, Y.-C., Lin, K.-P., Hoh, C.K., Huang, S.-C., Hoffman, E.J., Utilization of 3-D Elastic Transformation in Registration of Chest X-ray CT and Whole Body PET. *IEEE Trans. Nucl. Sci. NS-44* **4**: 1606-1612, 1997.
4. Silverman DHS, Phelps ME, Application of positron emission tomography to evaluation of metabolism and blood flow in human brain: normal development, aging, dementia and stroke. *Molec. Genetics and Metab.* **74**:128-138, 2001.
5. Minoshima, S., K.A. Frey, J.H. Burdette, T. Vander Borcht, R.A. Koeppe, D.E. Kuhl, Interpretation of metabolic abnormalities in Alzheimer's disease using three-dimensional stereotactic surface projections (3D-SSP) and normal database. *Journal of Nuclear Medicine*. **36**:237P, 1995.
6. Ishii, K., Sakamoto, S., Sasaki, M., Kitagaki, H., Yamaji, S., Hashimoto, M., Imamura, T., Shimomura, T., Hirono, N., Mori, E., Cerebral glucose metabolism in patients with frontotemporal dementia. *J. Nucl. Medicine*. **39**:1875-1878, 1998.
7. Silverman D.H.S., Lu C.S., Wong G.R., Aung A.M.K., Czernin J., Phelps M.E., Small G.W., Dahlbom M. Comparison of methods for comparing brain images of individual cognitively impaired patients to a normal group. *Journal of Nuclear Medicine*, 42(suppl):224P, 2001.
8. Silverman D.H.S., Marseille D.M., Peng N.X., Dahlbom M., Small G.W., Chen W., Czernin J., Phelps M.E. Comparing brain PET scans of individuals undergoing dementia evaluation to co-registered normal databases: effect of varying how "Normal" is defined. *Journal of Nuclear Medicine*, 44(suppl):17P, 2003.
9. Minoshima S, Giordani B, Berent S, Frey K Foster NL, Kuhl DE. Metabolic reduction in the posterior cingulate cortex in very early Alzheimer's disease. *Ann Neurol* 1997; 42:85-94.
10. Silverman DHS, Small GW, Chang CY, Lu CS, Kung de Aburto MA, Chen W, Czernin J, et al. Positron emission tomography in evaluation of dementia: regional brain metabolism and long-term outcome. *JAMA* 2001; 286:2120-2127.
11. Silverman DHS, Gambhir SS, Huang HWC, Schwimmer J, Kim S, Small GW, Chodosh J, Czernin J, Phelps ME Evaluating early dementia with and without assessment of

- regional cerebral metabolism by PET: a comparison of predicted costs and benefits. *J Nucl Med.* 2002; 43:253-266.
12. Silverman DHS, Truong CT, Kim SK, Chang CY, Chen W, Kowell AP, Cummings JL, Czernin J, Small GW, Phelps ME. Prognostic value of regional cerebral metabolism in patients undergoing dementia evaluation: comparison to a quantifying parameter of subsequent cognitive performance and to prognostic assessment without PET. *Molec Gen and Metab*: 2003; 80:350-355.
 13. Silverman DHS. Brain F-18-FDG PET in the diagnosis of neurodegenerative dementias: comparison with perfusion SPECT and with clinical evaluations lacking nuclear imaging. *J Nucl Med.* 2004;45:594-607.
 14. Silverman DHS and Alavi A, PET imaging in the assessment of normal and impaired cognitive function. *Radiologic Clin North Am* Saunders/Elsevier, Philadelphia, 2005;43:67-77.
 15. Moulin-Romsee G, Maes A, Silverman D, Mortelmans L, Van Laere K. (2005) Cost-effectiveness of 18F-fluorodeoxyglucose positron emission tomography in the assessment of early dementia from a Belgian and European perspective. *Eur J Neurol.* 12:254-263.
 16. Daniel H.S. Silverman, M.D., Ph.D., Editor. (2009) PET in the Evaluation of Alzheimer's Disease and Related Disorders. *Springer*.
 17. Fleisher AS, Chen K, Liu X, Roontiva A, Thiyyagura P, Ayutyanont N, Joshi AD, Clark CM, Mintun MA, Pontecorvo MJ, Doraiswamy PM, Johnson KA, Skovronsky DM, Reiman EM. Using positron emission tomography and florbetapir f 18 to image cortical amyloid in patients with mild cognitive impairment or dementia due to Alzheimer disease. *Arch Neurol.* 2011; 68:1404-1411.
 18. Silverman DHS, Small GW, Chang CY, Lu CS, Kung de Aburto MA, Chen W, Czernin J, et al. Positron emission Silverman, D.H.S., Lu C.S., Wong G.R., Aung A.M.K., Czernin J., Phelps M.E., Small G.W., Dahlbom M. (2000) Development of standardized region of interest software for prognostic evaluation of early dementia. *Proc of the Intl Conf on Mathematics and Engineering Techniques in Med and Biol Sci*, 2:428.
 19. Weiner MW, Veitch DP, Aisen PS, Beckett LA, Cairns NJ, Green RC, Harvey D, Jack CR, Jagust W, Liu E, Morris JC, Petersen RC, Saykin AJ, Schmidt ME, Shaw L, Siuciak JA, Soares H, Toga AW, Trojanowski JQ; Alzheimer's Disease Neuroimaging Initiative. The Alzheimer's Disease Neuroimaging Initiative: A review of papers published since its inception. *Alzheimers Dement.* 2011 Oct 31. [Epub ahead of print]
 20. Jagust WJ, Bandy D, Chen K, Foster NL, Landau SM, Mathis CA, Price JC, Reiman EM, Skovronsky D, Koeppe RA; Alzheimer's Disease Neuroimaging Initiative. The Alzheimer's Disease Neuroimaging Initiative positron emission tomography core. *Alzheimers Dement.* 2010; 6:221-9. PubMed Central PMCID: PMC2920531.

Appendix I - BRAIN PET SCAN VISUAL INTERPRETATION

Examine for (and document where appropriate):

- a) adequacy of the technical quality of scan acquisition, reconstruction, and display,
- b) presence of any evident structural abnormality, including rating the degree of atrophy as either none, slight, mild, moderate, or severe,
- c) assessment of global level of cortical metabolism, relative to the levels visually evident in basal ganglia, thalamus, and cerebellum,
- d) presence of any focal cortical abnormalities (with locations specified as left or right dorsolateral prefrontal, medial prefrontal, anterior cingulate, inferior frontal, sensorimotor, superior parietal, inferior parietal, parietotemporal, superior temporal, mid-to-inferior anterior lateral temporal, mid-to-inferior posterior lateral temporal, mesial temporal, primary visual occipital, associative visual occipital, or posterior cingulate cortex),
- e) presence of any focal non-cortical abnormalities, including in left or right caudate nucleus head, lentiform nucleus, thalamus, cerebellar cortex, midbrain, pons, and
- f) any additional findings.

The cerebral metabolic findings noted from this systematic review of the PET should be correlated whenever possible with the structural information documented on CT or MRI, with respect to cerebrovascular disease, atrophic changes, and other structural imaging findings. Metabolic evidence of neurodegenerative processes (e.g., Alzheimer's disease, Pick's disease, and other frontotemporal dementia, dementia with Lewy bodies, dementia of Parkinson's disease, Huntington's disease) is most strongly supported by identification of areas of regional hypometabolism unmatched by structural findings (i.e., greater than could be expected for the degree of any generalized structural atrophic changes noted, and not accounted for by cerebrovascular changes).

Brain PET Scan CATEGORIES FOR DEMENTIA EVALUATIONS

Scans obtained in the evaluation of cognitive impairment can be classified into one of 7 main interpretive categories (**Figure 1**, adapted from Silverman et al., JAMA, 2001; 286:2120-2127) – normal (*N1*) or normal except for age-appropriate atrophic changes (*N2*); abnormal only in a non-neurodegenerative pattern (*N3*); abnormal in a neurodegenerative pattern involving posterior cortical hypometabolism consistent with presence of AD (*P1*); abnormal in a neurodegenerative pattern that includes posterior cortical hypometabolism but is nevertheless inconsistent with AD as the most likely or sole cause of cognitive impairment (*P1+*) (e.g., due to involvement of brain regions known to be preserved in AD, and/or lack of involvement of inferior parietal and posterior cingulate cortex); abnormal in a neurodegenerative pattern that is most consistent with frontotemporal dementia (*P2*), or a predominantly subcortical neurodegenerative process (*P3*).

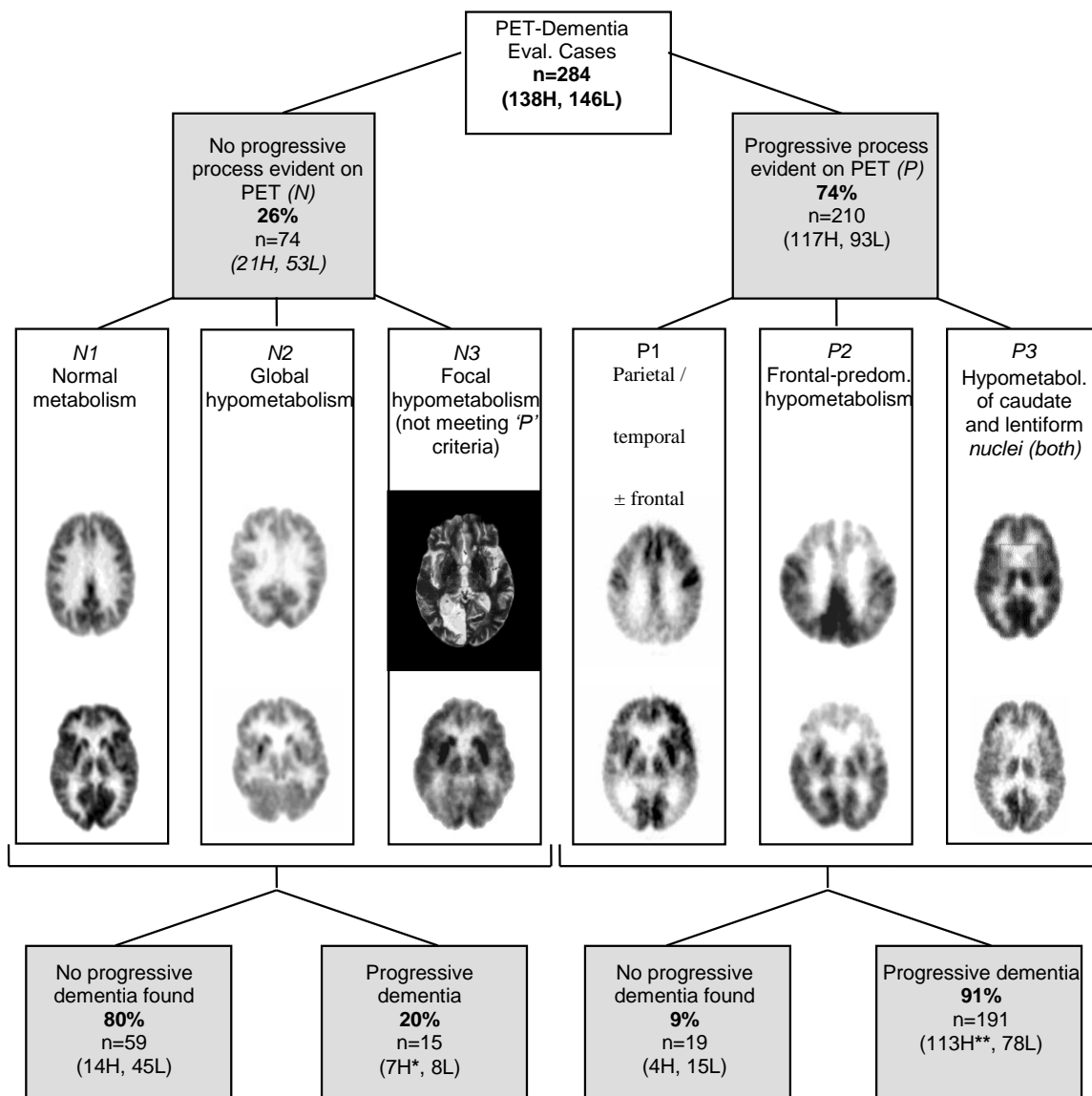


Figure 1. PET patterns and presence of progressive disease in patients undergoing evaluation for dementia.

PET scans typical of each of six categories of cerebral metabolic patterns (designated *N1*, *N2*, *N3*, *P1*, *P2*, *P3*) are demonstrated. Images displaying *N1*, *P1*, and *P3* patterns were acquired with a Siemens ECAT EXACT HR+ scanner; those displaying *N2*, *N3*, and *P2* patterns were acquired with a Siemens ECAT 931 scanner. Image set in black background was acquired using a GE Signa 1.5 T MRI scanner, TR=2100, TE=80. H, diagnosis established by histopathologic examination. L, outcome established by longitudinal monitoring.

* 3 AD, 1 AD + progressive supranuclear palsy, and 3 Creutzfeldt-Jakob cases.

** 86 AD, 4 AD + Lewy bodies, 1 AD + Parkinson's disease, 1 AD + cerebrovascular disease, 1 AD + Lewy bodies + cerebrovascular disease; 7 frontotemporal, 6 Lewy body, 3 subcortical gliosis, 2 Creutzfeldt-Jakob, 1 progressive supranuclear palsy, and 1 Kuf's lipofuscinosis case.

APPENDIX II - Regional Hypometabolism Identified by FDG-PET

CLINICAL BRAIN PET:

DIFFERENTIAL DIAGNOSIS OF DEMENTIA SYNDROMES

Etiology of Dementia	Regional Hypometabolism Identified by FDG-PET
Alzheimer's Disease	Parietal, temporal and posterior cingulate cortices affected early; relative sparing of primary sensorimotor and primary visual cortex; sparing of striatum, thalamus, and cerebellum.
Vascular Dementia	Hypometabolic foci affecting cortical, subcortical, and cerebellar areas.
Frontotemporal Dementia	Frontal cortex, anterior temporal and mesiotemporal areas affected earlier and/or with greater initial severity than parietal and lateral posterior temporal cortex; relative sparing of primary sensorimotor, posterior cingulate, and visual cortex.
Huntington's Disease	Caudate and lentiform nuclei affected early, with gradual development of diffuse cortical hypometabolism.
Parkinson's Dementia	Similar to Alzheimer's Disease, but less sparing of visual cortex. In early, untreated Parkinson's disease, basal ganglia may appear hypermetabolic.
Dementia with Lewy Bodies	Similar to Alzheimer's Disease, but less sparing of occipital cortex.

APPENDIX III – Medicare Checklist to Determine FDG-PET Dementia

CHECKLIST TO DETERMINE WHETHER FDG-PET DEMENTIA EVALUATION IS INDICATED AND COVERED BY MEDICARE*

1. Does the patient have diminished memory and other cognitive deficits which have been present for at least 6 months, and which now impair her or his ability to function as (s)he normally would (professionally, socially, or with respect to activities of daily living)?
___Yes (continue to #2) ___No PET scan is not covered.
2. Based on history, physical examination, and blood labs, is evidence present for any of the following correctable conditions:
Depression? Substance Abuse? Malnourishment? Medication Effects?
Cardiopulmonary compromise? Anemia? Hypoxemia? Infection? Thyroid dysfunction? Renal or hepatic disorder? Glucose or electrolyte/calcium dysregulation?
___Yes (continue to #3) ___No (continue to #4)
3. After treatment of the above condition(s), do the deficits still persist?
___Yes (continue to #4) ___No PET scan is not indicated.
4. Does the patient suffer from Alzheimer's disease, in the judgment of a physician experienced in the diagnosis and assessment of dementia who evaluated this patient, aided by:
a) cognitive scales or neuropsychological tests, b) corroborating history from a well-acquainted informant,
c) laboratory tests (including serum B12 and TSH levels) and structural imaging (MRI or CT)?
___Yes – the physician judges the presence of Alzheimer's disease to be certain
PET scan is not covered.
___No – the physician judges the absence of Alzheimer's disease to be certain
PET scan is not covered.
___Uncertain—the physician judges that it is uncertain whether the patient suffers from Alzheimer's disease
(continue to #5)
5. Does the patient exhibit symptoms (e.g., early onset or prominence of social disinhibition, awkwardness, difficulties with language, loss of executive function) such that frontotemporal dementia is suspected as an alternative cause of the patient's cognitive deficits?
___Yes (continue to #6) ___No PET scan is not covered.
6. Is it reasonable to expect that information obtained through FDG-PET will help with diagnosis and management of the patient?
___Yes (continue to #7) ___No PET scan is not covered.
7. Has the patient previously undergone SPECT or FDG-PET for the same indication?
___Yes – the results were conclusive and the patient's condition has not substantially changed
PET scan is not covered.
___Yes – but the results were not conclusive and at least a year has elapsed
(continue to #8)

___Yes – but there have been important changes in scope or severity of the patient’s cognitive deficits since then
(continue to #8)
___No (continue to #8)

8. **An FDG-PET scan is considered “reasonable and necessary” by CMS.** The patient should be referred to a facility accredited to operate Nuclear Medicine equipment and the scan should be read by an expert with experience interpreting PET scans for the evaluation of dementia.

To request a color-coded electronic copy of this Checklist, e-mail Dr. Dan Silverman at uclasomdan@yahoo.com.

Daniel H. Silverman, MD, PhD
Nuclear Medicine Clinic, Div. Biological Imaging
Dept. Molecular and Medical Pharmacology
University of California, Los Angeles

APPENDIX IV - USING CLINICAL BRAIN PET FOR EVALUATION OF DEMENTIA

Indication: Changes in memory, language function, personality, or behavior—noted by the patient, friends and family, and/or physician – for which the etiology is not evident, or the symptoms have not been reversed, within a reasonable period of time after initial presentation.

Acquisition Protocol: ^{18}F FDG (10 mCi for 2D acquisitions, 3.5-10 mCi for 3D acquisitions) administered i.v., 40 min uptake period with eyes open in dimly lit quiet room; followed by transmission and emission scans, reconstructed with attenuation correction.

Interpretation: A pattern of focal cortical inhomogeneities on PET, all accounted for by areas of infarction on MRI, implies dementia secondary to cerebrovascular disease, which also often affects subcortical structures. A pattern of focal cortical inhomogeneities on PET unmatched by MRI findings is consistent with a neurodegenerative disorder (e.g., Alzheimer's disease, Pick's disease, other frontotemporal dementia, dementia with Lewy bodies, dementia of Parkinson's disease, Huntington's disease, Creutzfeldt-Jacob disease, or progressive subcortical gliosis – see Table on page 1, for differential diagnostic considerations.)